Volume 1 (1) Jan-Jun 2022

Thai Endodontic Journal (ENDOSARN)

The official journal of the Thai Endodontic Association

TEJ





Interesting articles

- มิติใหม่ในการใช้เทคนิคการถ่ายภาพขั้นสูงในงานเอ็นโดดอนติกส์
- ผลของน้ำยาอีดีทีเอสูตรต่างๆ ต่อความมีชีวิตของเซลล์ต้นกำเนิดเนื้อเยื่อในโพรงประสาทฟัน
- Clinical considerations for non-vital tooth walking bleaching

ISSN 1685-3709

Text and Journal

Non-surgical endodontic treatment of mandibular left second premolar with gemination: a case report

Danuchit Banomyong[1]

Roongrawee Kamolroongwarakul[1]

[1] Department of Operative Dentistry and Endodontics, Faculty of Dentistry, Mahidol University, Bangkok, Thailand

Abstract

Objective: This case report describes a non-surgical endodontic treatment of mandibular left second premolar with gemination that had carious exposed pulp.

Case report: In a Thai male patient aged 35 years old, clinical examination, periapical radiographs at different horizontal angles, and cone-beam computed tomography (CBCT) were performed to investigate the unusual anatomy of coronal structure and root canal system in mandibular left second premolar with gemination. The gemination tooth had one large pulp chamber and two separated root canals, which then joined at the apical third of the root, with a presence of an incomplete isthmus. After caries removal, non-surgical endodontic treatment was performed under consideration of the unusual root canal system. Coronal access was modified following the anatomy of the large pulp chamber. Mesial and distal root canals were located and instrumented with rotary Ni-Ti files (Twisted Files, Sybron Endo, Orange, CA, USA) with a copious amount of irrigants and passive ultrasonic irrigation technique. A combination of lateral and warm vertical compaction, as a hybrid technique, was used to obtain three-dimensional obturation in the unusual root canal system. A prefabricated fiber post and resin composite core build-up restoration was placed as an intermediate restoration. The patient was recalled to evaluate the successful outcome of treatment. At one-year recall, the tooth was asymptomatic. From the radiograph, PDL space was normal and lamina dura was intact.

Conclusion: With a specific consideration of unusual root canal anatomy, the geminated mandibular second premolar with pulpal and periapical pathosis can be successfully treated by non-surgical endodontic treatment.

Keywords: double tooth, gemination, geminated tooth, non-surgical root canal treatment, root canal anatomy

How to cite: Banomyong D, Kamolroongwarakul R. Non-surgical endodontic treatment of mandibular left second premolar with gemination: a case report. Thai Endod J 2022; 1: 59-70.

Corresponding author: Danuchit Banomyong

Department of Operative Dentistry and Endodontics, Faculty of Dentistry, Mahidol University, Bangkok, Thailand

Email address: Danuchit Banomyong danuchit.ban@mahidol.ac.th

Roongrawee Kamolroongwarakul roongrawee.kam@gmail.com

Received: 24 February 2022 Revised: 19 April 2022 Accepted: 20 April 2022

Introduction

Gemination is a type of tooth anomaly- an incomplete dividing of one tooth bud into two during tooth development (1, 2). Commonly, a gemination tooth has completely or partially separated two crowns with the presence of a single root (1). The etiology of gemination is still unclear; genetic relation or dental trauma to tooth bud has been proposed (1). Fusion is another tooth variation that has a clinical appearance similar to gemination. Fusion is a combination of two teeth, partially or totally, which may be a result of close contact between two tooth buds during tooth formation (1). Fused teeth are usually present as separated two crowns with two distinct roots (2). However, the appearances of gemination and fusion teeth depend on the degree of developmental anomalies (3). A neutral term such as 'double tooth' has been suggested (1, 2).

The incidence of gemination is very low, which is less than 1% in studied populations (4). The incidences in permanent dentitions are 0-0.2% and 0-0.05% for unilateral and bilateral existences, respectively. A higher incidence of gemination is reported among Asians and American Indians (1). Nevertheless, incidences between the two genders are similar (1). Gemination is usually found in anterior regions of the maxilla and mandible while posterior teeth are rarely geminated that gemination in posterior teeth is generally presented in case reports (1, 5).

Pulpal pathosis might occur in the geminated teeth (6). A longitudinal deep groove may present between two separated crowns with a discontinuing of enamel and/or cementum. This unprotected dentin may be a pathway for bacteria invading dental pulp (6). The other cause is proximal contact with the adjacent teeth may be improper due to the unusual shape of the gemination tooth. This potentially induces food retention and proximal caries that may involve the pulp if left untreated.

The root canal system of a gemination tooth is unusual and sometimes complex, depending on the degrees of gemination (7, 8). At the coronal level, the pulp chamber may be present as a single large or two separated compartments. At the radicular level, two separated root canals in a single root are commonly found, which are usually then joined at the apical portion (4). Moreover, minor communication, such as isthmus or fin, frequently exists between the main root canals (4).

Comprehensive clinical and radiographic examinations are necessary to gather information on unusual root canal anatomy. In gemination teeth, multiple radiographs with different horizontal angles should be taken (9). Cone-beam computed tomography (CBCT) may be useful to obtain three-dimensional images of the root canal system (10). Endodontic treatment in gemination teeth would be complicated and should be performed under consideration of unusual root canal morphology.

The purpose of this case report was to demonstrate non-surgical endodontic treatment in a geminated mandibular left second premolar with a carious pulpal exposure.

Case report

A healthy, Thai male patient aged 35 years old was present at the endodontic clinic of the Faculty of Dentistry, Mahidol University, Bangkok, Thailand.

His chief complaint was having spontaneous pain on and off at the mandibular left second premolar for a few months. The tooth was moderately sensitive when drinking cold water, and the sensitivity lasted for several minutes. Occasionally, the patient took 1-2 tabs of 500 mg acetaminophen for relieving pain, but none of the dental treatment was previously obtained. By that time, all symptoms were subsided, so the tooth was asymptomatic.

Clinical and radiographic examinations

The coronal structure of the mandibular left second premolar showed an anatomical variation, which was similar to two 'bifid' premolars (**Fig.1A**). This anatomical-variated tooth had deep distal caries which would be exposed pulp and two small occlusal caries. The coronal anatomical structure of the mandibular right second premolar on the opposite side was normal (**Fig.1B**).

The tooth was mildly painful to percussion, but normal to palpation. No swelling or sinus tract was observed. Tooth mobility was at the first degree without periodontal involvement, and probing depths were 2-3 mm. The tooth was not responding to electrical pulp testing (EPT) while the control tooth was positive for the test.

Periapical radiographic examination, using a parallel technique (**Fig.2A-C**), showed a large radiolucent area at the distal coronal portion, which was deep proximal caries. A large pulp chamber was noticed, which was divided into mesial and distal root canals at the cementoenamel junction (CEJ) level. The two main canals were likely to be joined and curved distally at the apical level. Only one large, the conical-shaped root was observed. In the periapical area, lamina dura was intact, but periodontal ligament (PDL) space was thickening. In addition, mesial- and distal-shifted radiographs were also taken (**Fig.2A-C**).

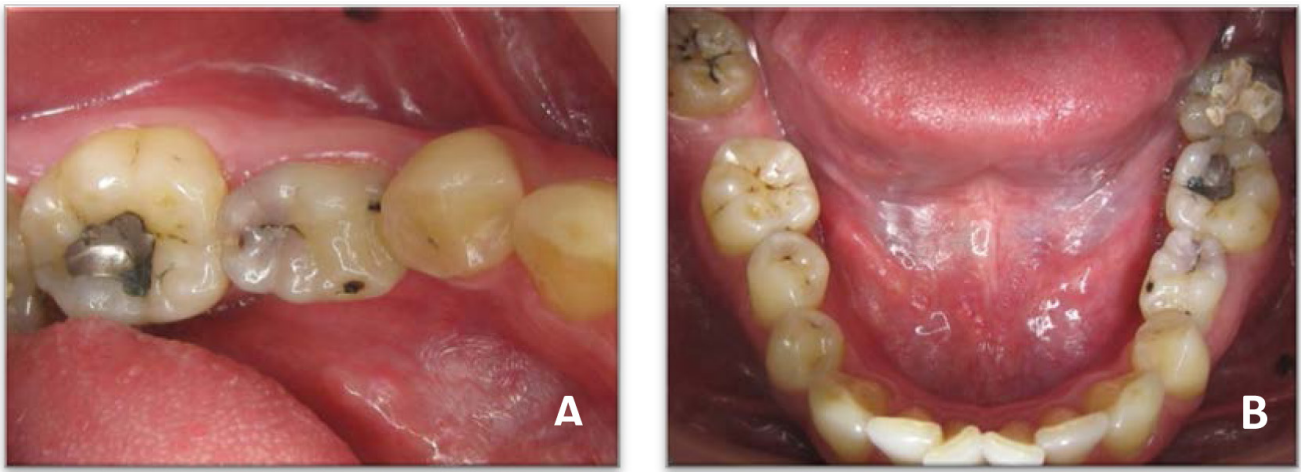

Figure 1: A- The mandibular left second premolar showed an anatomical variation, which was similar to two 'bifid' premolars. Severe discoloration under the distal marginal ridge was distinctly observed because of deep proximal caries. In addition, two small occlusal caries were detected on the occlusal surface. B- Size and shape of mandibular right second premolar were normal, in comparison to mandibular left second premolar with the anatomical variation.

Figure 2: Periapical parallel radiographs of mandibular left second premolar with gemination were taken from different horizontal angles- mesial shifted (A), straight-on (B), and distal shifted (C). Deep proximal caries was found on the distal side, and a large pulp chamber was observed. Mesial and distal root canals were visible separately at the coronal two-thirds but joined at the apical level. Only one large, the conical-shaped root was noticed.

CBCT in a small field of view and voxel size of 0.125 mm was taken to investigate three-dimensional information on the root canal system (**Fig.3A-D**). From CBCT images, mesial and distal canals seemed to be not completely separated at the middle level. However, a thin radiolucent line of the small isthmus, as a communication between the two canals, was not clearly observed due to the limitation in the resolution of CBCT. Thickening of PDL space was noticed in the periradicular area.

Clinical diagnosis and treatment planning

Pulpal exposure was confirmed after complete caries removal. From clinical and radiographic examinations, the tooth was initially diagnosed as pulp necrosis and symptomatic apical periodontitis with the anatomical variation, namely gemination. Non-surgical root canal treatment and post/core with crown restoration were planned, but the definitive restoration was delayed since the patient had a budget problem. Resin composite restoration with the placement of prefabricated fiber post was alternatively planned as intermediate restoration.

Non-surgical endodontic treatment

At the first visit, a dental clamp was applied to the adjacent tooth since it could not find a perfect fit clamp on the unusual-shape geminated tooth. Under rubber dam isolation, distal caries was completely removed without local anesthetic administration, and a pulpal exposure site was found. Coronal access was opened following the outline of a large pulp chamber, and then mesial and distal canal orifices with inter-canal isthmus were located (**Fig.4A**). However, a painful sensation occurred while inserting size #10 K-file deep into the root canals. Local anesthesia 1.8 ml of 2% Mepivacaine (Septodont, Saint-Maur-des-fossés, Cedex, France) containing epinephrine 1:100,000 was administered using an inferior alveolar nerve block. Remnants of pulp tissues were found and completely removed using size #10 K-file by the filing action. The coronal distal wall was built up with glass-ionomer cement and resin composite.

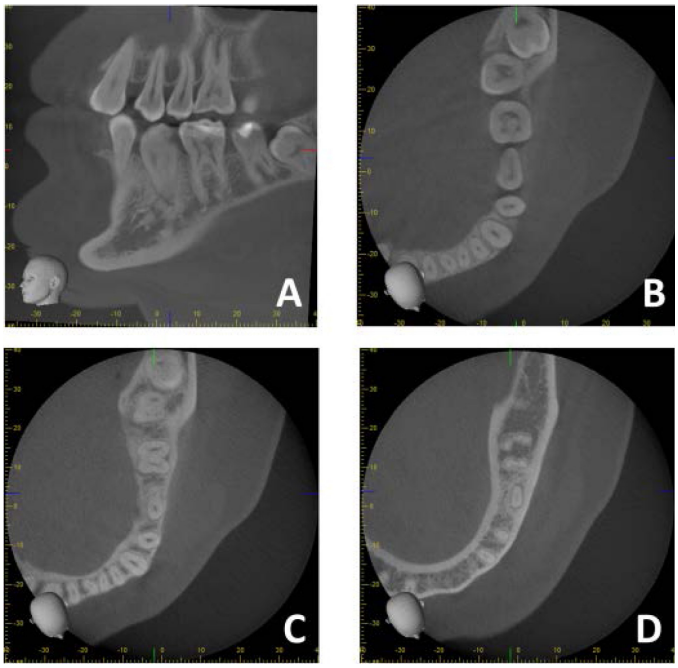

Figure 3: CBCT images of the mandibular left second premolar. A- sagittal view, B- axial view at the coronal one-third of the root, C- axial view at the middle one-third of the root, and D- axial view at the apical one-third of the root.

The coronal access was re-shaped, and canal orifices were flared with ultrasonic tips (ET20D and ET25, Satelec-Acteon, Mount Laurel, NJ, USA) to remove cervical dentin (**Fig. 4B**). The canals were explored with size #10 K-file to confirm the patency of canals, and it was found that the apical portion of root canals (around 2 mm) was curved to the distal site.

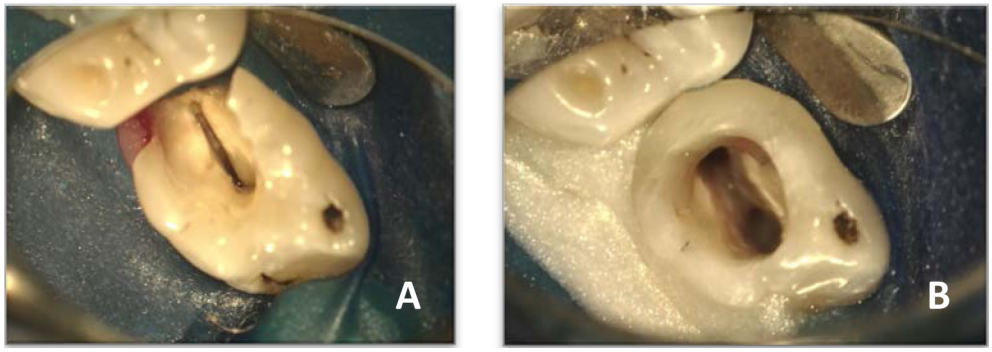

Figure 4: A- The geminated left mandibular second premolar after distal caries removal and access opening, in which mesial and distal canal orifices with inter-canal isthmus were detected. After distal caries was removed, the distal gingival margin was sub-gingival, and the rubber dam isolation was not fully covered in the area. B- The geminated premolar after the wall was built-up with resin composite and complete coronal flaring using ultrasonic tips.

Working length (WL) was initially determined using an electronic apex locator (Root ZX, J. Morita, Osaka, Japan). Estimated WLs were 21.0 and 20.0 mm for mesial and distal canals, respectively. Glide paths in mesial and distal canals were created using size #10-15 K-files. The estimated WLs were confirmed by a radiograph, in which the two canals were joined at the apical one-third level (**Fig. 5A**). The canals were irrigated with 2.5% NaOCl and 17% ethylenediaminetetraacetic acid (EDTA) (using a 5-cc syringe and an open-end irrigation needle [size 25], inserted into the middle to the apical level of root canal depending on the stage of root canal preparation), dried with paper points, and then medicated with calcium hydroxide paste. Coronal access was temporarily sealed with zinc-oxide-based temporary restorative materials (Cavit and IRM).

At the next visit about two weeks later, the patient reported the tooth was asymptomatic, and temporary restoration was intact. Under rubber dam isolation, temporary restoration was removed, and root canal instrumentation was performed using a modified crown-down technique with the Ni-Ti rotary files (Twisted Files, Sybron Endo, Orange, CA, USA). In brief, a coronal two-third portion of root canals was mechanically instrumented using the Ni-Ti rotary TF files with sizes 25/.08 and 25/.06, sequentially. Next, the apical one-third portion of the mesial canal was mechanically instrumented using the rotary files with sizes 25/.04 and 25/.06, sequentially, to the level of working length. For the distal canal, the apical one-third portion was mechanically instrumented using the rotary files with sizes 25/.04, 25/.06, and 30/.06 to the level of joined canals. EDTA paste (Premier Dental, Plymouth, PA, USA) was used as a lubricant and 2.5% NaOCl was used as a root canal irrigant. In addition, a recapitulation using size #10 K-file at the working length was performed to facilitate debris removal at the apical area.

Gutta-percha main cones size 25/.06 and 30/.06 were tried in the mesial and distal canals and radiographically checked (**Fig.5B**). The canals were irrigated with 5 ml 2.5% NaOCl and 3 ml 17% EDTA

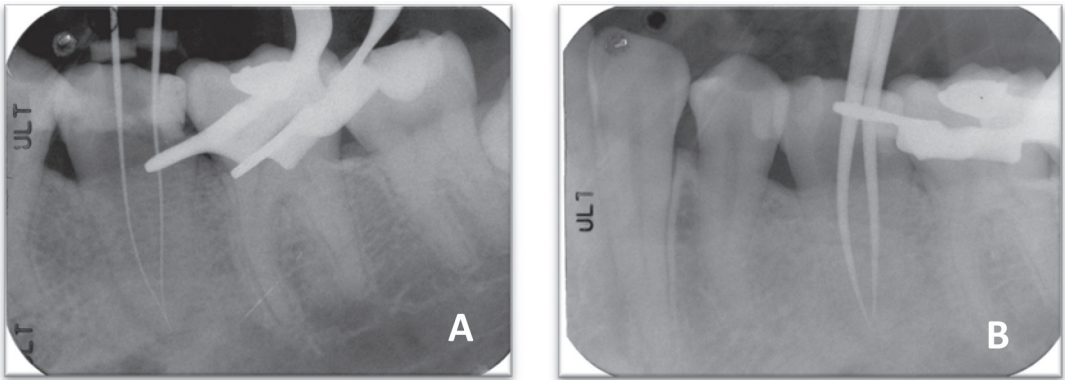

Figure 5: A- Radiographic image of working length determination. Mesial and distal canals were joined at the 2-mm level from the working length. B- Radiographic image of the two greater-taper main cones within the prepared canals (25/.06 for mesial canal and 30/.06 for distal canal) after mechanical instrumentation of the canals with the rotary Ni-Ti files.

for 1 minute with an insertion depth of irrigation needle tip at approximately 1-2 mm from the WL. When the final irrigation with 5 ml 2.5% NaOCl, the passive ultrasonic irrigation (PUI) technique was employed using the Irrisafe tip size #20 (Satelec-Acteon) for 3 minutes (3 cycles, 1 minute of each). The canals were dried with paper points and medicated with calcium hydroxide paste. Coronal access was temporarily sealed with Cavit and IRM.

At the third visit approximately four weeks later, the patient reported tooth was asymptomatic, and temporary restoration was intact. Under rubber dam isolation, temporary restoration was removed. The canals were finally irrigated with 2.5% NaOCl/ 17% EDTA (without PUI) and dried with paper points. The root canals were obturated using the hybrid technique (a combination of lateral compaction and warm vertical compaction) with an epoxy resin-based root canal sealer (AH Plus, Dentsply-Maillefer, Tulsa, OK, USA). Gutta-percha was down-packing to the 4-5 mm level from working length with the electrically heated pluggers (System B, Sybron Endo; tip sizes .08 and .06, sequentially). Flowing of gutta-percha and/or sealer into the isthmus area between two root canals was observed (**Fig. 6**). Moreover, the filled lateral canals and sealer extrusion were detected in the apical area (**Fig. 6**). As planned, a post space in 7.5 mm depth was immediately prepared in the mesial canal after the down-packing step, in which the canal was additionally filled with thermoplasticized gutta-percha for 1-2 mm. The gutta-percha was left apically intact for 6-mm length, and the intracanal depth of the post at 7.5 mm was equal to the height of the coronal tooth structure. For the distal canal, after the down-packing step, the canal was filled up to the orifice level with thermoplasticized gutta-percha injection using an electrical heated, gutta-percha injection unit (Sybron Endo). The coronal access was sealed with Cavit and IRM. The patient was referred to a restorative dentist for fiber-post placement (**Fig.7**) and resin composite restoration.

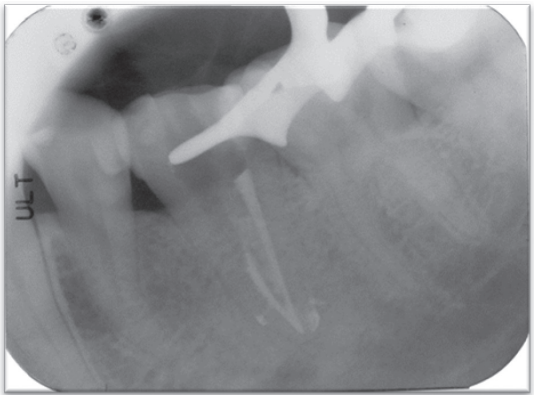

Figure 6: Radiographic image of mesial and distal root canals filled with gutta-percha and epoxy resin-based sealer using lateral compaction in a combination with warm vertical compaction (the hybrid technique). Post space was prepared in the mesial canal. Flowing of gutta-percha and/or sealer into the isthmus area between the two root canals was observed. Furthermore, the filled lateral canals and sealer extrusion were detected at the apical level.

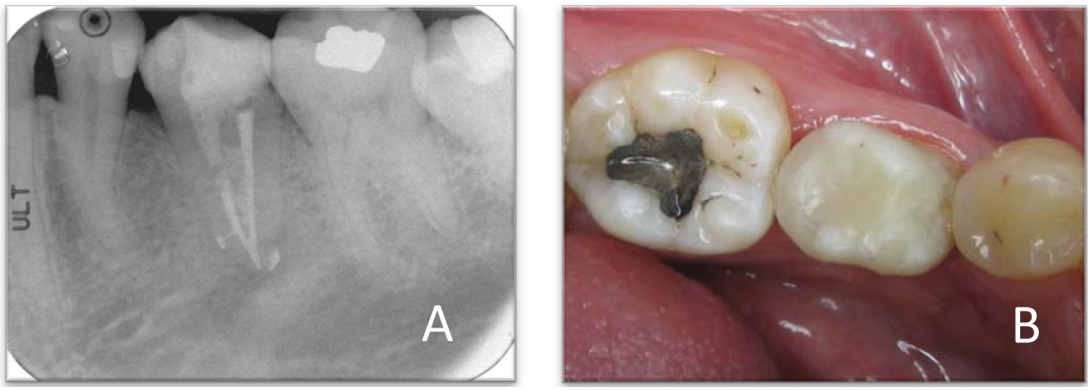

Figure 7: A- Radiographic image of the obturated root canals with a prefabricated fiber post cemented in the mesial canal and resin composite coronal restoration. Few voids were observed within the restoration. B- Clinical photograph of the geminated premolar after complete root canal treatment and resin composite restoration.

At one-year recall after complete root canal treatment, the patient reported the tooth was asymptomatic, and the restoration was intact. From the radiograph (**Fig.8**), PDL space was normal and lamina dura was intact. The extruded sealers were still present.

Figure 8: Radiographic image of the root-canal treated gemination tooth at one-year recall. The patient reported the tooth was asymptomatic. From the radiograph, the pre-operative PDL thickening was absent with normal intact lamina dura. However, the extruded sealers were still present. The defect at the gingival margin of restoration was observed, which was clinically secondary caries at the early stage.

Discussion

Gemination in the posterior tooth is a rare incidence. However, a preference for gemination occurrence has been reported in the Asian population (1). The incidence of unilateral gemination is higher than that of bilateral occurrence (4). In this Thai patient, the gemination presented unilaterally at the left mandibular second premolar, while the clinical appearance of the right premolar was normal.

In this case, clinical examination revealed two incompletely separated crowns on the mandibular second premolar. An overall number of remaining teeth was normal if the gemination tooth was counted as one. A single root with two root canals was detected in periapical radiographs. Thus, the tooth was diagnosed as gemination, rather than fusion.

Multiple radiographs with different horizontal angles did not reveal the anatomy of the root canal system in this case. Therefore, CBCT was employed to obtain three-dimensional information on the root canal system (10). The unusual anatomical variations were taken into the consideration in the proper endodontic treatment plan.

A suitable clamp should be firstly tried on a gemination tooth to check the stability on the atypical coronal tooth structure (11); clamp placement on an adjacent tooth is an alternative. In this case, the stability of the dental clamp as inadequate due to the unequal buccolingual widths at the cervical areas of the buccal and lingual sides. Thus, the clamp was placed on the first molar instead, and a flowable resin barrier was used to seal any gap between the rubber dam sheet and the tooth.

The tooth was not responding to the electrical pulp testing, so the clinical diagnosis of pulpal status was pulp necrosis. No pulpal tissue was left in the pulp chamber and coronal third of root canals after coronal access opening. However, the patient was painful when insertion a file deep into the canals. This can be explained by the pulp remnants inside the canals that were later removed after local anesthetic administration.

Access opening must be modified following aberrant coronal and radicular anatomies (4). In the case of two distinct pulp chambers, two separated accesses can be opened (6, 8, 12). In contrast, coronal access may be only one large portal if the two pulp chambers are almost or completely combined (7, 12). In this case, single access was prepared to conform with the outline of a large pulp chamber, in which the access was wide in a mesiodistal direction. For coronal flaring, cervical dentin was pronounced around the canal orifices and along the upper portion of the isthmus. Ultrasonic tips were used to remove cervical dentin around the orifices, and the isthmus area was also flared. An incomplete septum was found between the two canals (13). CBCT image revealed an isthmus between the two canals at the middle level, which was potentially below the septum.

Cleaning and shaping the root canal system of the gemination tooth must follow its unusual root canal anatomy. Additionally, in this case, the main root canals were narrow, joined, and

curved at the apical level. To prevent the separation of the rotary Ni-Ti files, glide paths were obtained (14). The mesial canal was determined as the main canal and instrumented to the working length because the path of file insertion at the apical area was easier with less force resistance. The distal canal was prepared only at the joined area to prevent file breakage since the canal seemed to be curved abruptly beyond that area. The effectiveness of cleaning the root canal system in the irregular isthmus areas could be improved by increasing the volume of irrigants (15) and using the PUI technique (16).

The presence of an incomplete isthmus makes optimal obturation in such an area is not possible by the lateral compaction (17). Warm vertical compaction is better alternative obturation of root canal with irregularities (7, 12). In this case, the hybrid obturation technique was employed since the D11TS hand-spreader could be inserted alongside the matched cones to 2-3 mm from the working length. To increase the amount of gutta-percha, the hybrid technique was used.

Sealer extrusions through main apical foramen and lateral canals were evidenced. The patient reported a minor uncomfortable sensation after root canal obturation for a few days, and no analgesics. The success rate of root canal treatment is commonly not reduced by the presence of sealer extrusion (18). However, the extrusion of sealer could delay the healing of periapical lesions (18). In this case, there was just a thickening of periodontal space with intact lamina dura in the preoperative radiograph. Hence, the extrusion of the sealer may not be significant even though it was not resorbed.

Final restoration for a gemination tooth with anatomical modification in coronal shape and size must be considered (2). In this case, the remaining tooth structure of the gemination tooth was less than half, so post and crown restoration was planned. However, the definite restoration has been delayed, and resin composite and fiber post were placed as intermediate restoration. When the post was already placed, a restorative dentist can prepare the tooth for the crown without re-entry into the canal. However, maintaining oral hygiene is important. The patient did not use dental floss regularly, so recurrent caries was formed at the gingival margin. In addition, the improper contour of restoration was also probably a cause of caries formation. At the recall visit, the patient was referred to a restorative dentist to repair the restoration.

Conclusion

Gemination mandibular premolar with pulpal and periapical pathology can be successfully treated by non-surgical endodontic treatment. Unusual anatomical variations must be carefully taken into the consideration, which leads to proper treatment and successful outcomes.

Acknowledgment

None

Funding source

None

Conflict of interest

None

References

1. Schuurs AH, van Loveren C. Double teeth: review of the literature. ASDC J Dent Child. 2000; 67: 313-25.
2. Shah P, Chander JM, Noar J, Ashley PF. Management of 'double teeth' in children and adolescents. Int J Paediatr Dent. 2012; 22: 419-26.
3. Sharma D, Bansel H, Snadhu SV, Bhullar RK, Bhandari R, Kakkar T. Fusion: A case report and review of literature. J Craniomaxillofac Surg. 2012; 1: 114-8.
4. Kremeier K, Hulsmann M. Fusion and gemination of teeth: review of the literature, treatment consideration, and report of cases. Endo Practice Today. 2007; 1: 111-23.
5. Kulkarni S, Meghana SM, Yadav M. Bilateral double teeth- A case report. Open J Stomatol. 2012; 2: 366-8.
6. Nahmias Y, Rampado ME. Root-canal treatment of a trifid crown premolar. Int Endod J. 2002; 35: 390-4.
7. Kremeier K, Pontius O, Klaiber B, Hulsmann M. Nonsurgical endodontic management of a double tooth: a case report. Int Endod J. 2007; 40: 908-15.
8. Aryanpour S, Bercy P, Van Nieuwenhuysen JP. Endodontic and periodontal treatments of a geminated mandibular first premolar. Int Endod J. 2002; 35: 209-14.
9. Rodig T, Hulsmann M. Diagnosis and root canal treatment of a mandibular second premolar with three root canals. Int Endod J. 2003; 36: 912-9.
10. Keys WF, Keightley AJ, Welbury RR. Sectioning of a double tooth aided by cone-beam computed tomography. Eur Arch Paediatr Dent. 2013; 14: 167-71.
11. Aguiar CM. Endodontic treatment of a geminated maxillary left first premolar: a case report. Acta Stomatol Croatia. 2011; 45: 215-9.
12. Tsesis I, Steinbock N, Rosenberg E, Kaufman AY. Endodontic treatment of developmental anomalies in posterior teeth: treatment of geminated/fused teeth--report of two cases. Int Endod J. 2003; 36: 372-9.
13. Fan B, Pan Y, Gao Y, Fang F, Wu Q, Gutmann JL. Three-dimensional morphologic analysis of isthmuses in the mesial roots of mandibular molars. J Endod. 2010; 36: 1866-9.
14. Alves Vde O, Bueno CE, Cunha RS, Pinheiro SL, Fontana CE, de Martin AS. Comparison among manual instruments and PathFile and Mtwo rotary instruments to create a glide path in the root canal preparation of curved canals. J Endod. 2012; 38: 117-20.
15. Siqueira JF, Jr., Rocas IN, Favieri A, Lima KC. Chemomechanical reduction of the bacterial population in the root canal after instrumentation and irrigation with 1%, 2.5%, and 5.25% sodium hypochlorite. J Endod. 2000; 26: 331-4.
16. van der Sluis LW, Versluis M, Wu MK, Wesselink PR. Passive ultrasonic irrigation of the root canal: a review of the literature. Int Endod J. 2007; 40: 415-26.

17. Endal U, Shen Y, Knut A, Gao Y, Haapasalo M. A high-resolution computed tomographic study of changes in root canal isthmus area by instrumentation and root filling. J Endod. 2011; 37: 223-7.

18. Sari S, Duruturk L. Radiographic evaluation of periapical healing of permanent teeth with periapical lesions after extrusion of AH Plus sealer. Oral Surg Oral Med Oral Pathol Oral Radiol Endod. 2007; 104: e54-9.