Volume 1 (1) Jan-Jun 2022

Thai Endodontic Journal (ENDOSARN)

The official journal of the Thai Endodontic Association

TEJ





Interesting articles

- มิติใหม่ในการใช้เทคนิคการถ่ายภาพขั้นสูงในงานเอ็นโดดอนติกส์
- ผลของน้ำยาอีดีทีเอสูตรต่างๆ ต่อความมีชีวิตของเซลล์ต้นกำเนิดเนื้อเยื่อในโพรงประสาทฟัน
- Clinical considerations for non-vital tooth walking bleaching

ISSN 1685-3709

Text and Journal

Clinical considerations for non-vital tooth walking bleaching

Danuchit Banomyong

Department of Operative Dentistry and Endodontics, Faculty of Dentistry, Mahidol University

Abstract

Root canal-treated teeth with coronal discoloration require esthetic improvement. The causes of discoloration should be evaluated for the proper treatment plan, and technical procedures of non-vital tooth bleaching should be carefully considered. Non-vital tooth walking bleaching is a simple, conservative, safe, effective, and low-cost procedure. This review article will focus on considerations in step-by-step for intracoronal 'walking' tooth bleaching to correct tooth discoloration after endodontic treatment. These important considerations are cleaned pulp chamber, appropriate level of gutta-percha, effective cervical seal, proper placement of bleaching agent, adequate temporary seal, and delay in permanent restoration.

How to cite: Banomyong D. Clinical considerations for non-vital tooth walking bleaching. Thai Endod J 2022; 1: 33-42.

Introduction

Many root canal-treated teeth encounter the problem of coronal discoloration that requires an esthetic improvement after root canal treatment. Non-vital tooth walking bleaching is a conservative approach that preserves the natural tooth structure with a satisfying intermediate- to long-term result [1, 2]. Other non-conservative treatments, such as a direct/indirect veneer or full-coverage crown, should only be considered when the non-vital tooth bleaching is unsuccessful, enormous loss of tooth structure, or modification of tooth shape is required. The objectives of this review article are to explain the causes of discoloration in non-vital teeth, and the considerations for the 'walking' bleaching.

Causes of discoloration in non-vital teeth

The discoloration of non-vital teeth is mainly noticeable in upper central and lateral incisors (90% approximately), which dental trauma was the most common cause (60% approximately) [1]. Non-vital teeth may be discolored because of pulpal necrosis, intrapulpal hemorrhage, pulp tissue remnant, endodontic sealer/gutta-percha, or intracanal medicaments [3]. Nevertheless, tooth discoloration from these factors can be prevented or reduced during endodontic procedures. Necrotic pulpal tissues can induce tooth discoloration by the decomposing products and must be completely removed during access opening, without the remaining roof of the pulp chamber or pulp horn.

Corresponding author: Danuchit Banomyong

Department of Operative Dentistry and Endodontics, Faculty of Dentistry, Mahidol University, Bangkok, Thailand

Email: danuchit.ban@mahidol.ac.th

Received: 7 March 2022 Revised: 29 April 2022 Accepted: 7 May 2022

In a case with irreversible pulpitis, excessive pulpal bleeding should be controlled by immediate pulp removal, and any blood remnants on dentinal walls must be cleaned with sodium hypochlorite solution to prevent the internal staining of dentine.

In the previously treated teeth, tooth discoloration from the root canal obturation materials may be visible, especially in the tooth with a thin labial or buccal structure. Gutta-percha obturation material should be seared off and plugged at the level of 1–2 mm below the cementoenamel junction. In addition, any remnant of root canal sealer (e.g. epoxy resin sealer) in the pulp chamber should be also effectively cleaned. Cleaning with alcohol-soaked micro-brush before air-water spray can remove more than 90% of sealer remnants and is significantly better than cleaning with alcohol-soaked cotton, slow-speed-bur grinding, or aluminum oxide air polishing [4, 5]. In contrast, calcium silicate (bioceramic) sealer can be easily cleaned with air-water spray only [5]. In a case using a three-mixed antibiotic paste containing minocycline or other intracanal medicament containing tetracycline derivative (e.g. Ledermix paste), the medicament should be carefully placed only below the pulp chamber [6, 7]. Moreover, the pulp chamber may be coated with a dental adhesive (e.g. Clearfil SE Bond, Kuraray, Japan) before medicating to prevent or reduce any discoloration from the medicament.

Considerations for non-vital tooth 'walking' bleaching

The principle of the intracoronal-approach technique is based on the placement of a bleaching agent left inside the pulp chamber for a period of week while the coronal access is filled with a temporary restoration. The treatment can be repeated by the replacement of a bleaching agent if the whitening effect has not reached the satisfactory level. The non-vital tooth 'walking' bleaching is simple, conservative, safe, effective, and low-cost procedure. This 'internal' bleaching technique can be used in combination with the 'external' bleaching, which is a chair-side or home bleaching method generally used for whitening of vital teeth if the whitening result is not satisfying after 3-4 times of internal bleaching [3]. However, in the tooth that does not effectively respond to the bleaching, a veneer or crown may be considered as a complete resolution of the remaining discoloration.

Bleaching agent

Intracoronal 'walking' bleaching regularly uses sodium perborate [$2x(NaBO_2(OH)_2).n(H_2O)$] powder mixed with distilled water or 3–6% hydrogen peroxide solution, depending on the severity of discoloration. The sodium perborate mixed with 3% hydrogen peroxide shows the superior whitening effect on non-vital teeth compared to the bleaching agent only, which should be used for the severely discolored teeth [8]. The chemical reaction of sodium perborate mixed with distilled water produces the reactive ingredient– hydrogen peroxide [9].

$$2[NaBO_2(OH)_2] + 2H_2O \rightarrow 2Na^+ + 2[H_2BO_3]^- + 2H_2O_2$$

A slow-releasing injectable 35% hydrogen peroxide gel (e.g. Opalescence Endo, Ultradent,

South Jordan, UT, USA), a strong peroxide-based agent, can be also used for intracoronal walking bleaching with similar effectiveness, but in a shorter application period (only 3-5 days of each appointment) than using sodium perborate mixed 3% hydrogen peroxide [8, 10]. This product is commonly in a ready-used syringe form that no mixing is required. However, the greater diffusion of hydroxyl ions into cementum and the higher increase of pH at the external root surface compared to sodium perborate is reported [11]. This may increase a risk of cervical root resorption if a cervical barrier is not properly created before bleaching. In addition, the ready-used bleaching agent is commonly high-cost and has a short shelf life. Apart from the hydrogen peroxide gel, 35-37% carbamide peroxide gel (e.g. Opalescence PF 35%, Ultradent, which is approximately equal to 12% hydrogen peroxide) may be used in the walking bleaching [12].

Procedures of internal walking bleaching for non-vital tooth

The procedures of intracoronal non-vital tooth 'walking' bleach technique using sodium perborate powder mixed with distilled water or hydrogen peroxide solution were described as follows in step-by-step and considerations for clinical success [3, 9].

Pre-bleaching preparation

To begin with, the root-filled tooth is clinically and radiographically examined. The root canal obturation must be qualified, where the retreatment is not needed. Pre-operative shade selection should be performed with a proper shade guide such as Vitapan Classic ™, arranged in the value from the lightest to the darkest shades in **Fig.1**, to record a baseline color for comparison even the discoloration is beyond the shade-guide value. For the non-vital tooth bleaching with 2-3 appointments, the average tooth shade change is approximately 12 levels of the shade guide, in which 4-6 shades improvement is expected in each visit [13].

Figure 1 A shade guide, arranged in the lightest to the darkest tooth shades according to the value, starting from B1 (the highest value) to C4 (the lowest value) for pre-operative shade determination.

Access opening

Under rubber dam isolation, coronal access is prepared by removal of existing restoration to the level of gutta-percha obturation material. The pulp chamber must be cleaned without the remnants of gutta percha or/and root canal sealer. Severely discolored dentine may be partially removed to relieve the difficulty in bleaching. If the level of gutta-percha obturation is too high, it should be removed to 1–2 mm below the cementoenamel junction (**Fig.2**).

Cervical seal (barrier)

One of the most important steps to prevent a complication (i.e. cervical root resorption) after non-vital tooth bleaching is to create the cervical seal [3, 9, 14]. The defects in cementum at the cementoenamel junction (relating to exposed cervical dentine) are present approximately 10% of teeth that allows hydrogen peroxide diffusion through dentinal tubules to the external tooth surface during intracoronal bleaching. The peroxide diffusion into the periodontium possibly increases a risk of cervical root resorption especially when high-concentration hydrogen peroxide and thermocatalytic method are used. In contrast, using low-concentration peroxide agents are unlikely to induce the resorption [15]. A glass-ionomer cement (such as Fuji IX [GC corp., Tokyo, Japan], or Vitrebond [3M ESPE, St. Paul, MN, USA]) is commonly used for the creation of the cervical seal in approximately 2-mm thick (**Fig.2**) [16].

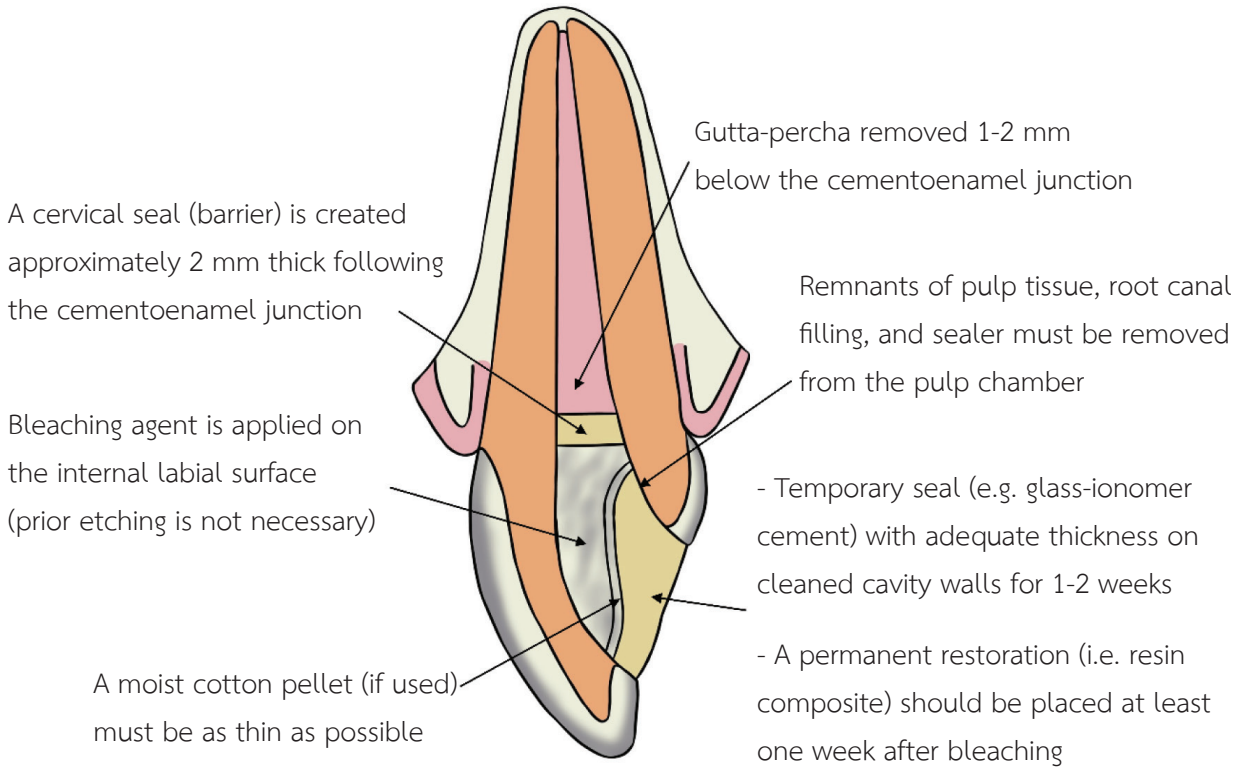

Figure 2 An illustration of key considerations for clinical success in non-vital tooth walking bleaching.

The cervical seal should conform to the cementoenamel junction in both labio-lingual and mesio-distal sides (**Fig.3**) to prevent the diffusion of peroxide into the cementum and periodontal ligament [11, 17], which may induce the inflammatory-related cervical root resorption [18]. The level of the cervical seal (in relation to the cementoenamel junction/ labial gingival margin) should be carefully checked with a periodontal probe.

Figure 3 A cervical seal should be created following the level of cementoenamel junction. Therefore, the cervical seal at the mesial and distal sides (white arrows) are generally higher than those at the labial and palatal sides.

Application of bleaching agent

A bleaching agent (sodium perborate powder) is mixed with distilled water (in a ratio of 2:1, $g.mL^{-1}$) to achieve a thick paste. The concentration of the mixture is approximately 3% hydrogen peroxide [9]. In case of severe discoloration, sodium perborate powder can be mixed with 3–6% hydrogen peroxide solution; a risk of cervical resorption is very minimal when low concentration hydrogen peroxide is used with a presence of cervical barrier [15]. For the ready-used bleaching gel, it can be injected from the syringe directly into the pulp chamber.

The mixed bleaching agent is carried into the pulp chamber using a clean amalgam carrier (a small-size tip) and gently packed with a plugger or paper points. The most important area on which the bleaching agent should be applied is the internal labial wall (**Fig.2**). The more contact and the higher amount of bleaching agent on the surface, the better whitening effect is anticipated.

A thermocatalytic technique using a strong bleaching agent and heat application is contraindicated since this technique is associated with the incidence of cervical root resorption [9]. Etching with phosphoric acid, in an attempt to remove the smear layer and open dentinal tubules, before application of bleaching agent is not necessarily due to insignificantly bleaching improvement [19, 20].

Subsequently, excessive bleaching agents on the cavity walls must be completely cleaned before temporization; otherwise, the coronal seal of temporary restoration would be affected. A thin moist cotton pellet may be placed over the bleaching agent as a source of moisture for the reaction of sodium perborate. However, this may be not essential because of sufficient water content in the mixture. The moist cotton pellet may be used if the bleaching agent is too dry before loading into the pulp chamber. However, the pellet should be leaved as thin as possible (**Fig.2**), or removed after rewetting the bleaching agent. Otherwise, the thickness and the seal of temporary restoration may be compromised.

Temporary seal

A temporary seal is required to prevent leakage of bleaching ingredients (**Fig.2**). The cavity walls must be thoroughly cleaned and free of bleaching agent remnants, e.g. by using a small bonding applicator, before temporary restoration. The remaining cavity depth above the bleaching agent is usually not adequate (in particular at the cervical margin) for Cavit or IRM temporary materials that require at least 3–4 mm thickness for acceptable seal [2]. A force from packing temporary filling may also displace the bleaching agent away from the labial wall. Furthermore, the IRM material contains the eugenol that remains inside dentinal tubules, which conceivably induces further discoloration as well as interrupts polymerization reaction of a resin-based restoration. When Cavit material is used, a cotton pellet moistened with bonding agent may be placed on the bleaching agent and then light cured, which this 'pellet' layer can protect bleaching agent from dislocation during placement of temporary filling.

More importantly, the higher amount of peroxide used, the more oxygen release is observed, so that a temporary restoration must effectively seal to avoid marginal leakage [21]. For these reasons, the preferable material should be restorative-type glass-ionomer cement (e.g. Fuji IX or Fuji II LC), which the minimally required thickness of glass-ionomer cement to achieve the coronal seal is approximately 2 mm [16]. The glass-ionomer cements can be used with the hand-mixed type combined with a Centrix syringe; otherwise, the easy-to-use encapsulated type is also available. The mixed material of glass-ionomer cement is flowable and injectable from the syringe/capsule tip, or applied with a Dycal carrier to fill the cavity without the packing force. Flowable resin composite is another alternative option, but this resin-based material needs acid etching that tends to wash out the applied bleaching agent. Otherwise, the enamel must be etched and rinsed before application of bleaching, or a self-etching adhesive may be rather used.

Evaluation appointment

It is generally recommended that the patient should be recalled at approximately one week to monitor the color change of the tooth [3]. From a laboratory study, the optimal renewal time of bleaching-agent at 1-2 days has been suggested, which the release of active peroxide gradually decreases over the 5-day observation period [22]. However, no clinical study on a proper duration of non-vital bleaching has been found. The recall period may be shorter (i.e. 3-5 days) if a strong, ready-used product (e.g. 35% hydrogen peroxide gel Opalescence Endo) is used. The repetition of intracoronal walking bleaching may be required if the bleaching effect is not adequate. One to four appointments may be required for the bleaching, which should be informed to patients before treatment [3, 9]. The average number of appointments for non-vital tooth walking bleaching is 2-3 visits [13]. Non-vital bleaching in the elderly teeth may require a longer period to achieve a satisfied result than that in the young teeth [22, 23].

If the bleaching effect is slightly less than the desired level (compared to the color of adjacent vital teeth), the external chair-side (in-office) bleaching using a high-concentration

(30-40%) hydrogen peroxide may be helpful to immediately increase the whitening effect [2]. At home bleaching with 10-20% carbamide peroxide using whitening trays may be an alternative or a combination of treatment [24].

On the other hand, over-bleaching may occur. Appropriate recall period at approximately one week and patient self-notification of whitened tooth color are important. The patient should be informed for contact the dentist before the appointment if he/she notices that the treated tooth becomes whiter than the others.

Permanent restoration

After achieving the satisfactory outcome of whitening, the bleaching agent is removed, and the cavity is cleaned and temporarily restored. Calcium hydroxide paste may be placed before temporization [25] in an attempt to reverse the acidic pH change in the cementum and periodontal ligament, but this is likely to be unnecessary since the cervical seal is created [15].

A resin composite restoration should not be immediately placed, and at least a one-week delayed period is suggested [26]. The explanation is that the remnants of free-radical peroxide left inside dentinal tubules strongly interfere with the polymerization reaction of adhesive and resin composite. The bond strength of immediately restored resin composite restoration of the bleached tooth is significantly lower than that of the non-bleached tooth. The reduced bond strength is recovery if the restoration is placed one week later [26]. A water chasing agent (e.g. alcohol or acetone) may be applied before restoration to reduce the adverse effect of bleaching on adhesion to enamel; however, the bond strength is just partially reversed [27].

Clinical outcome

The immediate outcome of the current walking bleach technique is approximately 90% success, which the overall patients' satisfaction is as high as 95% [13]. A representative case of non-vital tooth walking bleaching is shown in **Fig.4**.

Figure 4 Clinical outcome of non-vital tooth walking bleaching on maxillary right lateral incisor using sodium perborate powder mixed with distilled water for a total of 2-week period, which the patient was recalled and the bleaching agent was changed once at 1 week.

The relapse in discoloration may occur over a period (20% at 3 years, and approximately one-third of cases after 16 years) [1, 28]. However, the re-bleaching can be performed to improve the esthetic performance. For a color-relapsed tooth, external bleaching may be indicated to avoid re-entry into the pulp chamber [2]. Combination of in-office bleaching and subsequent internal walking bleaching reduces the color relapse to approximately 15% after 24 years [29].

In the past, cervical root resorption was a serious complication that was usually found after the thermocatalytic bleaching with a high-concentration (35-40%) hydrogen peroxide agent and heat application (**Fig.5**). Nowadays, cervical resorption is rarely found in non-vital bleaching cases [1, 28, 30] with the creation of a cervical barrier and using a low-concentration (equal to 3-10% hydrogen peroxide) bleaching agent without heat stimulation. Therefore, the current intracoronal bleaching method is clinically safe [14, 15, 31].

Conclusion

Non-vital tooth intracoronal walking bleaching using sodium perborate powder mixed with distilled water or low-concentration hydrogen peroxide solution is conservative and effective with high clinical success. This technique is safe if a cervical seal is properly created and a heat application is avoidable. Therefore, the walking bleach technique is recommended as the first treatment option for discolored root-filled teeth. The main clinical considerations for success of non-vital tooth walking bleaching are (a) any remnants cleaned from the pulp chamber; (b) gutta-percha level below the orifice; (c) cervical seal created following the cementoenamel junction; (d) bleaching agent applied on internal labial surface; (e) adequate thickness of temporary seal (e.g. glass-ionomer cement); and (f) delay placement of permanent restoration at least one week after bleaching.

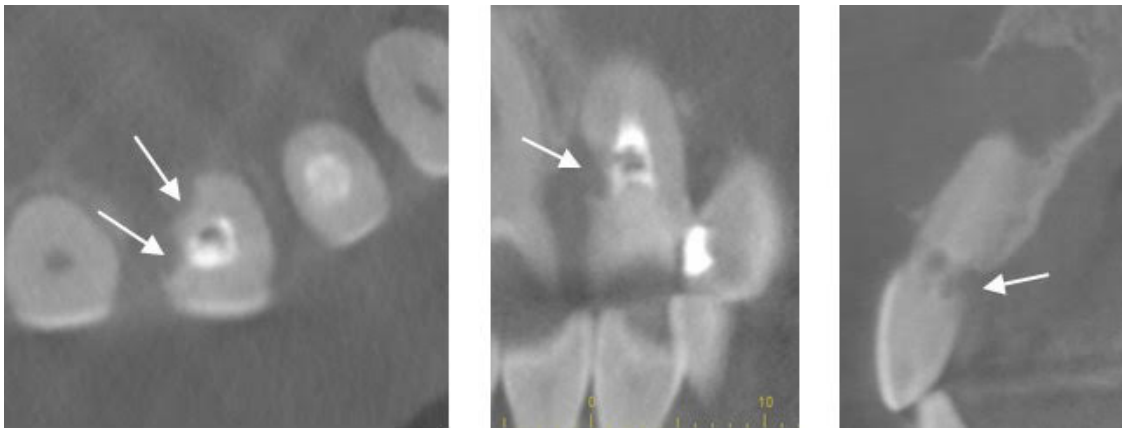

Figure 5 A cervical external root resorption on maxillary left central incisor with a history of non-vital tooth bleaching is observed in the cone-beam computed tomographic images (axial, coronal, and sagittal views respectively). A large defect of the cervical barrier is noticed.

Conflict of interest

none

Funding

N/A

Acknowledgement

N/A

References

1. Abbott P, Heah SY. Internal bleaching of teeth: an analysis of 255 teeth. **Aust Dent J**. 2009; 54: 326-33.
2. Greenwall-Cohen J, Greenwall LH. The single discoloured tooth: vital and non-vital bleaching techniques. **Br Dent J**. 2019; 226: 839-49.
3. Plotino G, Buono L, Grande NM, Pameijer CH, Somma F. Nonvital tooth bleaching: a review of the literature and clinical procedures. **J Endod**. 2008; 34: 394-407.
4. Ekici MA, Ekici A, Kaskatı T, Helvacıoğlu Kıvanç B. Tooth crown discoloration induced by endodontic sealers: a 3-year ex vivo evaluation. **Clin Oral Investig**. 2019; 23: 2097-102.
5. Devroey S, Calberson F, Meire M. The efficacy of different cleaning protocols for the sealer-contaminated access cavity. **Clin Oral Investig**. 2020; 24: 4101-7.
6. Kim ST, Abbott PV, McGinley P. The effects of Ledermix paste on discolouration of immature teeth. **Int Endod J**. 2000; 33: 233-7.
7. Athanassiadis B, Abbott PV, Walsh LJ. Mechanisms of Staining with Demeclocycline and Doxycycline Root Canal Medicaments. **Eur Endod J**. 2018; 3: 66-72.
8. Frank AC, Kanzow P, Rödig T, Wiegand A. Comparison of the Bleaching Efficacy of Different Agents Used for Internal Bleaching: A Systematic Review and Meta-Analysis. **J Endod**. 2022; 48: 171-8.
9. Attin T, Paqué F, Ajam F, Lennon AM. Review of the current status of tooth whitening with the walking bleach technique. **Int Endod J**. 2003; 36: 313-29.
10. Lim MY, Lum SO, Poh RS, Lee GP, Lim KC. An in vitro comparison of the bleaching efficacy of 35% carbamide peroxide with established intracoronal bleaching agents. ***Int Endod J***. 2004;37: 483-8.
11. Lee GP, Lee MY, Lum SO, Poh RS, Lim KC. Extraradicular diffusion of hydrogen peroxide and pH changes associated with intracoronal bleaching of discoloured teeth using different bleaching agents. **Int Endod J**. 2004; 37: 500-6.
12. Teixeira EC, Hara AT, Serra MC. Use of 37% carbamide peroxide in the walking bleach technique: a case report. **Quintessence Int**. 2004; 35: 97-102.
13. Gupta SK, Saxena P. Evaluation of patient satisfaction after non-vital bleaching in traumatized discolored intact anterior teeth. **Dent Traumatol**. 2014; 30: 396-9.
14. Kahler B. Present status and future directions – Managing discoloured teeth. **Int Endod J**. 2022; (*in press*).
15. Newton R, Hayes J. The association of external cervical resorption with modern internal bleaching protocols: what is the current evidence? **Br Dent J**. 2020; 228: 333-7.
16. Lim KC. Considerations in intracoronal bleaching. **Aust Endod J**. 2004; 30: 69-73.

17. Bersezio C, Estay J, Sáez M, Sánchez F, Vernal R, Fernández E. Six-month Follow-up of the Effect of Nonvital Bleaching on IL-1β and RANK-L: A Randomized Clinical Trial. **Oper Dent**. 2019; 44: 581-8.
18. Friedman S. Internal bleaching: long-term outcomes and complications. **J Am Dent Assoc**. 1997;128 Suppl:51s-5s.
19. Casey LJ, Schindler WG, Murata SM, Burgess JO. The use of dentinal etching with endodontic bleaching procedures. **J Endod**. 1989; 15: 535-8.
20. Horn DJ, Hicks ML, Bulan-Brady J. Effect of smear layer removal on bleaching of human teeth in vitro. **J Endod**. 1998; 24: 791-5.
21. Pallarés-Serrano A, Pallarés-Serrano A, Pallarés-Serrano S, Pallarés-Sabater A. Study of the intra-coronal pressure generated by internal bleaching agents and its influence on temporary restoration. **Applied Sciences**. 2022; 12: 2799.
22. Camps J, de Franceschi H, Idir F, Roland C, About I. Time-course diffusion of hydrogen peroxide through human dentin: clinical significance for young tooth internal bleaching. ***J Endod***. 2007; 33: 455-9.
23. Coelho AS, Garrido L, Mota M, Marto CM, Amaro I, Carrilho E, et al. Non-Vital Tooth Bleaching Techniques: A Systematic Review. **Coatings**. 2020; 10: 61.
24. Bizhang M, Heiden A, Blunck U, Zimmer S, Seemann R, Roulet JF. Intracoronal bleaching of discolored non-vital teeth. **Oper Dent**. 2003; 28: 334-40.
25. Demarco FF, Freitas JM, Silva MP, Justino LM. Microleakage in endodontically treated teeth: influence of calcium hydroxide dressing following bleaching. **Int Endod J**. 2001; 34: 495-500.
26. Shinohara MS, Peris AR, Pimenta LA, Ambrosano GM. Shear bond strength evaluation of composite resin on enamel and dentin after nonvital bleaching. **J Esthet Restor Dent**. 2005; 17: 22-9.
27. Barghi N, Godwin JM. Reducing the adverse effect of bleaching on composite-enamel bond. **J Esthet Dent**. 1994; 6: 157-61.
28. Amato M, Scaravilli MS, Farella M, Riccitiello F. Bleaching teeth treated endodontically: long-term evaluation of a case series. **J Endod**. 2006; 32: 376-8.
29. Amato A, Caggiano M, Pantaleo G, Amato M. In-office and walking bleach dental treatments on endodontically-treated teeth: 25 years follow-up. **Minerva Stomatol**. 2018; 67: 225-30.
30. Mavridou AM, Bergmans L, Barendregt D, Lambrechts P. Descriptive Analysis of Factors Associated with External Cervical Resorption. **J Endod**. 2017; 43: 1602-10.
31. Zimmerli B, Jeger F, Lussi A. Bleaching of nonvital teeth. A clinically relevant literature review. **Schweiz Monatsschr Zahnmed**. 2010; 120: 306-20.