Volume 3(2) July - December 2024

Thai Endodontic Journal (ENDOSARN)
วารสารเอ็นโดดอนติกส์ไทย (เอ็นโดสาร)

The official journal of the Thai Endodontic Association

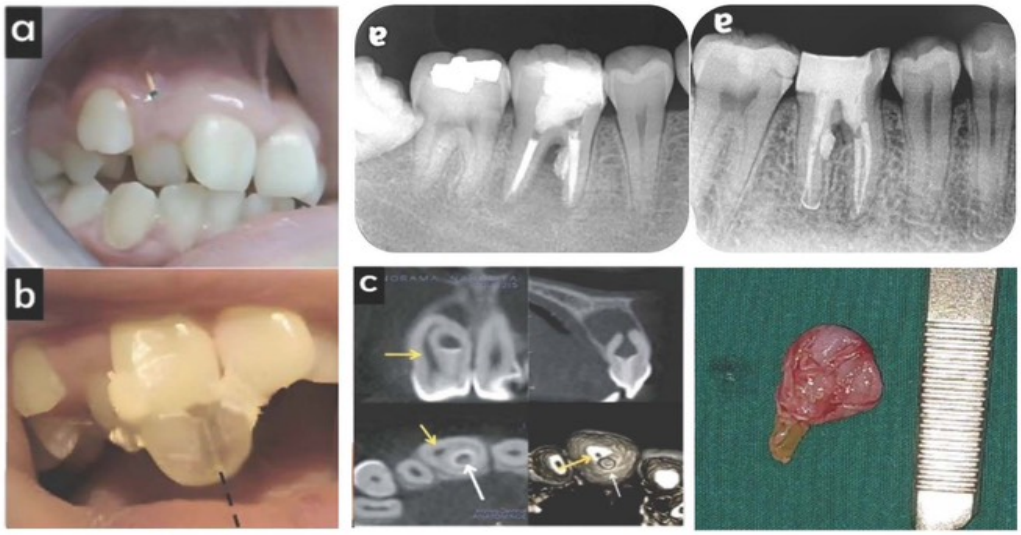

Interesting articles

- *Single-file rotary system: current concepts and their implementations*
- *Root Perforation Repair with Calcium Silicate Cements: Part 1- Basic Knowledge and Treatment Outcomes*
- *Root Perforation Repair with Calcium Silicate Cements: Part 2- Predictive Factors to the Outcome and Prognosis*
- *Management of external pressure resorption associated with dentigerous cyst: A case report*

Text and Journal Publication Co., LTD.

ISSN 1685-3709

Management of external pressure resorption associated with dentigerous cyst: A case report

Noppadol Sittithanaworakul[1]*, D.D.S., Higher Grad Dip.

Chanakarn Sinsareekul[2], D.D.S., FRCDS

Sirawut Hiran-us[3], D.D.S., M.Sc., Higher Grad Dip., FRCDS

[1] Department of Operative Dentistry, Faculty of Dentistry, Chulalongkorn University

[2] Department of Operative Dentistry, Faculty of Dentistry, Chulalongkorn University

[3] Department of Operative Dentistry, Faculty of Dentistry, Chulalongkorn University

Abstract

Pressure from cysts or tumors exerted on neighboring teeth may cause external surface resorption. Surgical removal of a cyst can compromise the vitality of the teeth by severing the nerve and blood supplies at the apices of the roots. In this case, a 60-year-old female presented with dull pain at the base of her nose and mobility of her anterior teeth. Teeth 11 and 21 were found to be associated with a dentigerous cyst of the embedded tooth (mesiodens) in the area. Tooth 21 exhibited clinical symptoms and a negative response to sensibility tests after the removal of embedded tooth and enucleation of the cyst, necessitating endodontic intervention. In contrast, the sensibility tests of tooth 11 recovered approximately two months after the surgical procedure. A follow-up appointment for sensibility testing and evaluation of clinical symptoms is suggested to determine the necessity of endodontic intervention for the tooth related to the temporary loss of sensibility resulting from the surgical procedures.

Keywords: External pressure resorption, External root resorption, Dentigerous cyst, Endodontic treatment

Correspondence: Noppadol Sittithanaworakul, D.D.S., Higher Grad Dip.

Department of Operative Dentistry, Faculty of Dentistry, Chulalongkorn University

Contact number: 064-565-3696

Email address: noppadol.si@chula.ac.th

Received: 25 October 2024 Revised: 11 December 2024 Accepted: 12 November 2024

Introduction

Root resorption refers to a condition associated with either physiological or pathological process that result in the loss of dental hard tissues due to a clastic effect (1). Causative factors such as injury or irritation lead to odontoclastic activity and the release of proinflammatory cytokine at the occurrence site, which is considered a normal inflammatory response to injury (2). The process gradually dissolves the root dentin and/or cementum layer, and endodontic treatment may be required in some types of resorptions, or in conjunction with other treatment modalities for a certain reason (3, 4).

External pressure resorption is considered one of the subtypes of root resorption and can be associated with various causative factors, including pressure from adjacent cysts or tumors (5) . Some types of cystic lesion are commonly found in the jaw and may relate to or approximate to root surface of certain tooth, depending on location of the lesion. Most of cystic lesion requires surgical interventions, either enucleation or marsupialization.

To date, management and case examples of teeth with external pressure resorption related to cystic lesion have been published in a relatively limited number of reports and case series. The purpose of this article is to report a case of external pressure resorption that requires endodontic treatment as a consequence of the enucleation of the associated cyst.

Case Report

A 60-year-old female with well-controlled type 2 diabetes mellitus and dyslipidemia was referred to the endodontic department for treatment of her two maxillary central incisors (teeth 11 and 21). The patient reported dull pain at the base of her nose, along with mobility of her anterior teeth. Upon examination, extraoral findings were normal. Intraoral examination revealed hard bony-like gingival swelling on the labial side **(Fig. 1)**. Teeth 11 and 21 had resin composite restorations at mesio-palatal aspect that were in good condition. Both teeth responded normally to pulp sensibility tests (electric pulp test [SybronEndo, CA, USA] and cold test [Endo-Frost: ROEKO Endo-Frost, Coltene, Switzerland] and were negative to percussion. Additionally, there were no periodontal pocket depth greater than 4 mm, tooth discoloration, and occlusal interference in either centric or eccentric position.

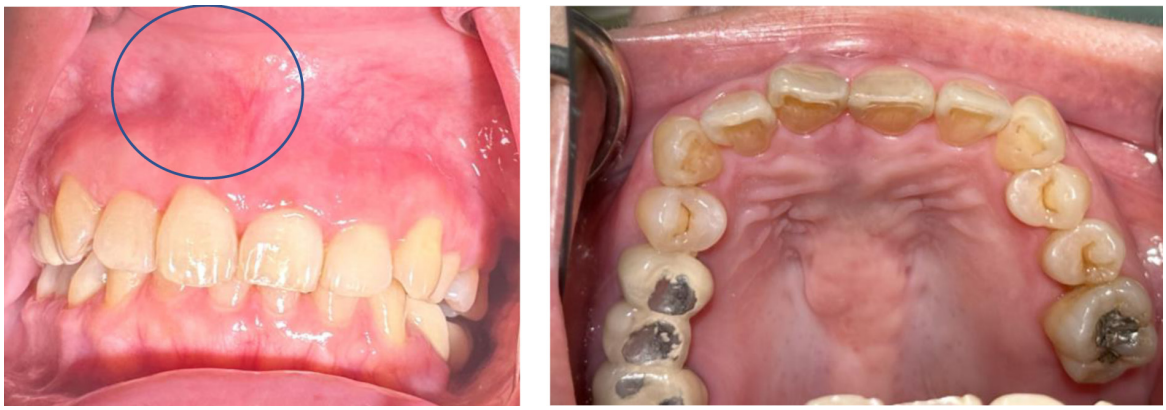

Figure 1 Clinical imaging before surgery showed that the gingival swelling on the labial side (blue circle line) and normal tissue on the palatal side.

Periapical radiographs showed a well-demarcated, unilocular mixed radiolucent-radiopaque lesion associated with the crown of supernumerary tooth (mesiodens) which located at the apices of tooth 11 and 21. **(Fig. 2)**. The apical regions of both teeth which exhibited evidence of external root resorption, were in direct contact with the cystic lesion.

From the clinical and radiographic data, a preliminary diagnosis of normal pulp with asymptomatic apical periodontitis with external pressure resorption associated with a cystic lesion and embedded mesiodens was made for both teeth. The differential diagnosis of this lesion are dentigerous cyst, calcifying odontogenic cysts, adenomatoid odontogenic tumors and nasopalatine duct cyst each determined based on location and radiographic characteristics. When a tooth is associated with the lesion, the most prevalent lesion is the dentigerous cyst, which has a pathognomonic sign of a radiolucent lesion with a well-defined border, attached at the cementoenamel junction of the tooth. Other lesions associated with the tooth include calcifying odontogenic cysts and adenomatoid odontogenic tumors, which are less frequent and often contain additional radiopaque material scattered within the lesion. These two lesions are commonly found in different locations: adenomatoid odontogenic tumors are mostly found in the maxilla, while calcifying odontogenic cysts are typically located in the mandible. However, the most common non-odontogenic lesion found at the midline of the anterior maxilla is the nasopalatine duct cyst. The patient was then referred to oral surgery department for the removal of cystic lesion and embedded mesiodens, with no indications for endodontic treatment.

Prior to the surgery, a dental cone-beam computed tomography (CBCT) scan was performed, revealing a cystic size of 12 x 15 x 18 millimeters,

Figure 2 The shifted tube radiographs taken before surgery indicated the position of the embedded mesiodens, showing that it is located palatally to tooth 21 and did not involve the root of tooth 22, as the lamina dura is intact, and the borders of the cystic lesion are situated between root of teeth 11 and 21.

leaning towards the labial aspect and encompassing the roots of teeth 11 and 21, with a slant-shaped and irregular surface on the external surface of roots. While the floor of nasal cavity remained intact **(Fig. 3)**.

During the operation, the surgeon carried out a flap procedure on the labial gingiva, aspirated the coffee-brown cystic contents, enucleated the cyst, and removed the mesiodens. The area was irrigated with normal saline, and sutures were placed using 4-0 Vicryl. The excised cystic lesion, along with the mesiodens **(Fig. 4)**, was sent for histopathological evaluation. The histopathological results revealed dense fibrous connective tissue walls lined by thin, non-keratinized stratified squamous epithelium, attaching to the cemento-enamel junction of a tooth, with infiltrating inflammatory cells, calcified materials and extravasated red blood cells. It was confirmed to be a dentigerous cyst.

The patient was then referred back to the endodontics department for re-evaluation of teeth 11 and 21 due to concerns about the vitality of these teeth resulting from potential disruption of nerve and blood supplies during the surgery.

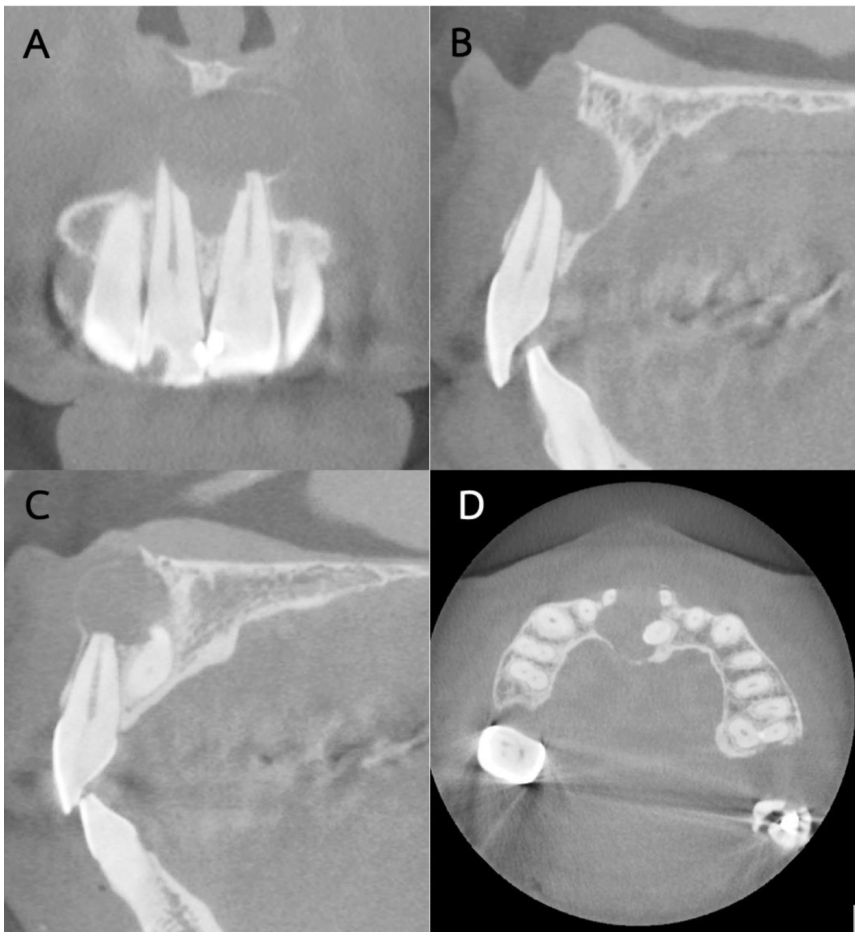

Figure 3 The cone-beam computed tomography images (A: Coronal view, B: Sagittal view of tooth 11, C: Sagittal view of tooth 21, and D: Axial view) show that the apices of teeth 11 and 21 are involved with the radiolucent lesion.

Figure 4 The excised cystic lesion, along with the mesiodens showed that the cystic lesion was attached to the cemento-enamel junction of the mesiodens.

Follow-up Examination 20 Days Post-Surgery

Patient showed normal extraoral appearance **(Fig. 5)**, with negative to sensibility tests on both teeth. Percussion and palpation testing revealed tenderness on tooth 21, while tooth 11 was normal response for both tests. No periodontal pockets, tooth discoloration, soft tissue swelling, sinus opening, or occlusal interference in either centric or eccentric positions were observed. Radiographically, both teeth remained unchanged in size and radiopacity compared to the pre-operative images, without any additional external root resorption noted **(Fig. 6)**. No treatment was given to tooth 11 during this appointment, as there was only one sign of a negative response to sensibility tests, which does not meet the criteria for endodontic therapy in traumatized teeth (6, 7) . Whereas a diagnosis of pulp necrosis with symptomatic apical periodontitis with external pressure resorption was made for tooth 21, as it exhibited pain upon percussion, indicating inflammation of periapical tissue likely resulting from diseased pulp. After rubber dam application, the cavity test was performed by drilling the access without using local anesthesia. The access to the root canal was completed with no bleeding, confirming the necrosis of the pulp and the necessity for root canal treatment. Working length was determined using an electronic apex locator and confirmed radiographically **(Fig.7A)**. The apical size was measured with K-file size 20. Instrumentation was completed with hand files, and 2.5% sodium hypochlorite was used as an irrigant throughout the procedure. Calcium hydroxide, and dual layers of Cavit and IRM were used as interappointment medication and temporary restoration, respectively.

Figure 5 Clinical images taken 20 days post-surgery showed that the gingival swelling on the labial side had disappeared.

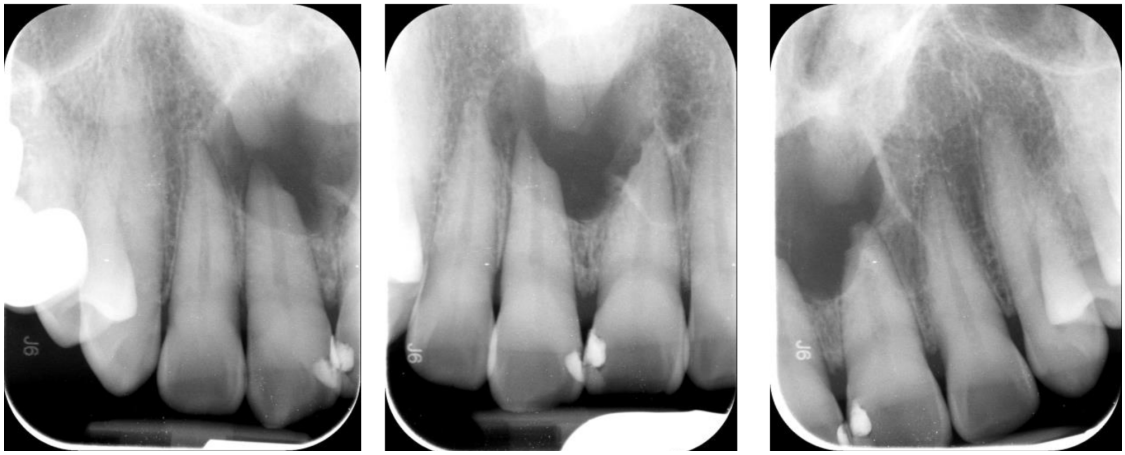

Figure 6 Radiographic images 20 days post-surgery showed that the lesion size and density is unchanged, and no additional root resorption is observed.

Second Visit (1 Month 20 days After surgery)

The patient was symptoms-free, with clinical examinations revealed normal response to percussion and palpation of tooth 11 and 21. Tooth 11 had regained its response to the sensibility test. Both teeth showed no signs of further external root resorption, and no washout of calcium hydroxide medication was observed for tooth 21 when evaluated radiographically **(Fig. 7B)**. Continuation of root canal treatment of tooth 21 was performed. After rubber dam application, temporary restoration and medicament were removed, gutta-percha main cone position was verified with radiograph **(Fig. 7C)**. The root canal was flushed with 5 ml of 17% ethylenediamine tetraacetic acid, followed by 2.5% sodium hypochlorite prior to obturation. Root canal was filled with gutta-percha and epoxy-resin based sealer [AH plus sealer; Dentsply Sirona] using lateral condensation technique **(Fig. 7D)**, and the tooth was permanently restored with glass ionomer cement and resin composite **(Fig. 7E)**.

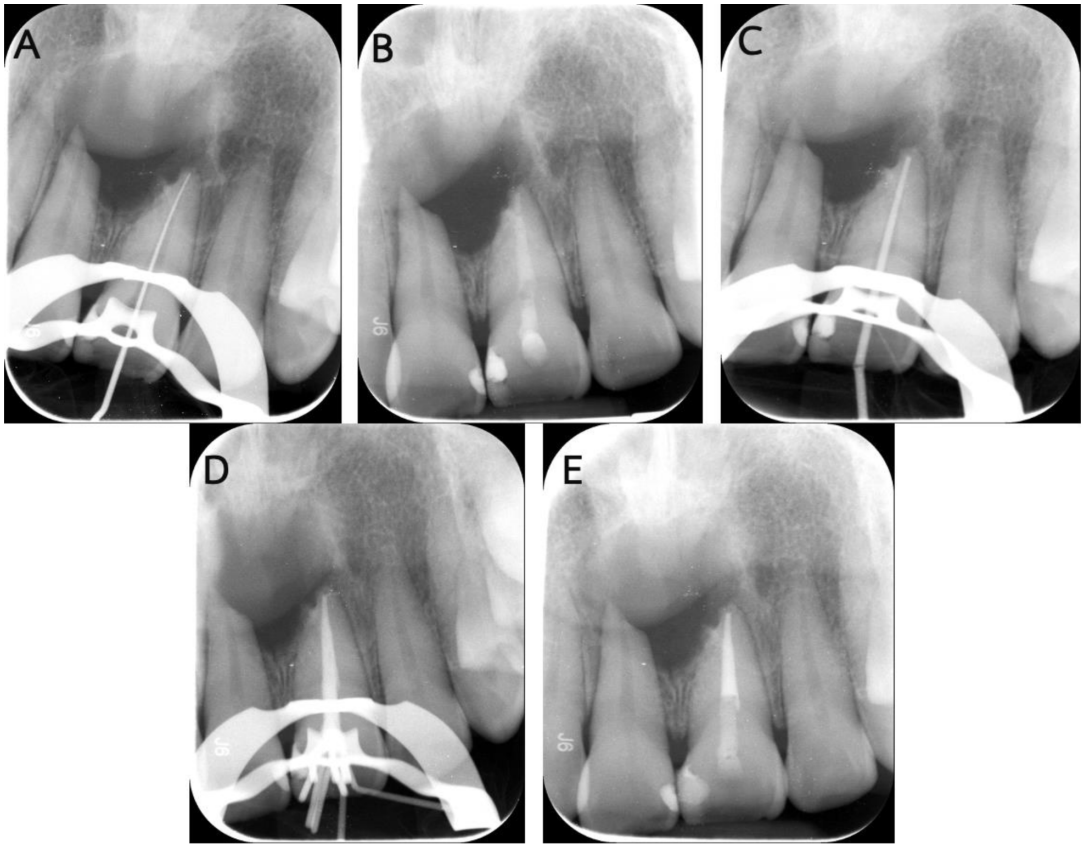

Figure 7 Radiographic images of clinical procedures: (A) Working length determination, (B) Absence of calcium hydroxide washout from the root canal, (C) Try main cone, (D) Root canal filling, (E) Final radiograph.

Follow-Up (3 Months Post-Surgery)

The patient remained symptoms-free, with no abnormalities found from clinical examination of teeth 11 and 21. Radiographs revealed no additional external root resorption at the apices of both teeth, with presence of lamina dura in tooth 21. Meanwhile, the lamina dura of tooth 11 was still untraceable, but the radiolucency involves periapex of tooth 11 was reduced in size when compared to pre-operative radiograph **(Fig. 8)**.

Follow-Up (1 Year Post-Surgery)

Both teeth were absence of subjective and clinical symptoms, no abnormalities were noted from examination. Radiographs showed no further signs of external root resorption, with intact lamina dura at the apices of both teeth which evaluated as completely healed. Moreover, the radiolucent area surrounding the apex of both roots had significantly decreased in size **(Fig. 8)**.

Figure 8 Radiographic follow-up: (Left) 3 months post-surgery, (Right) 1 year post-surgery.

Discussion

The treatment of asymptomatic teeth with external pressure resorption is often challenging due to the lack of evidence-based clinical practice guidelines. In the past, most dentists preferred elective endodontic therapy, while some experts support the possibility of preserving the remaining vital pulp without further intervention. This case report demonstrates an interdisciplinary approach to the management of teeth with external pressure resorption associated with dentigerous cyst.

External pressure resorption is the resorptive process that occurs when pressure is applied to the external surface of a tooth. The etiology can originate from either an adjacent impacted tooth or pathologic conditions (such as cysts or tumors) (8). Blood supplies in the periodontal ligament can be damaged due to compression, leading to hypoxic condition of the tooth. The elicited inflammatory response activates clastic cells, causing root resorption as the precementum and cementoblasts are damaged (9-11). In this case, it has shown that a dentigerous cyst, the most common odontogenic cyst, is associated with the external pressure resorption of both teeth. Consistent with previous study, Teo et al. found that root resorption was present in 41.2% of dentigerous cysts located in close proximity to adjacent teeth (12). Clinical presentation can be asymptomatic, with no signs of an apparent endodontic cause. The involved teeth usually respond to sensibility tests, which corresponds to the condition examined pre-operatively in this case report. However, some teeth may not response due to nerve compression from external pressure. Sensibility will typically return after the external pressure is removed.

Elimination of the cause of pressure is the key management for this type of resorption which can provide predictable results. Once the cyst is removed and the resorption has ceased, the root surface is capable of healing without any additional intervention. Resorptive defects are most likely to heal with the formation of cementum-like tissue, and the root surface contour may be partially repaired if the resorption previously involved the root dentin (13-16). These processes were reflected in the results of our radiographic examinations of

the tooth 11 at the end of the follow-up. Tooth 11 showed no clinical symptoms, with recovery of normal response to pulp sensibility tests approximately two months after surgery. Both teeth 11 and 21 had external pressure resorption, but root canal treatment is indicated only for tooth 21. This suggests that external pressure resorption itself neither an indication for root canal treatment, nor are other types of root resorptions such as orthodontic induced root resorption and invasive cervical root resorption. The diagnosis of pulpal and periapical tissue via thorough examination is still the fundamental philosophy for correct treatment planning. Only diseased pulp indicates the need for root canal treatment. According to the previous study (17), 54.3% of lesion-involved teeth developed pulp necrosis after surgical enucleation of the lesion, with a follow-up period of 8 to 72 months.

In the surgical procedure for this case, a flap incision and ostectomy were performed on the labial side because the labial bone of the lesion appeared to be thinner on the CBCT radiograph compared to palatal side. Even though the mesiodens was located palatally, this approach was chosen to avoid unnecessary bone removal, provide easier surgical access, offer a better direct visual field, and reduce the risk of injury to vital structures, such as the major nerve and blood vessel that distributed on palatal side.

Lesions with an ill-defined border and aggressive bony expansion, this may suggest a malignant tumor. An intentional pulpectomy should be performed on the affected tooth, followed by root curettage or apicoectomy as part of the surgical plan. This approach aims to avoid leaving any potential remnants of the cystic cells in the affected area, thereby preventing recurrence due to its high recurrence rate (18). In case, the lesion exhibited a well-defined border, no bony expansion, no aggressive swelling, and the involved tooth responded normally to the sensibility test. These findings led to the assumption that the lesion was likely a benign cyst or tumor (19). The surgical plan was to completely enucleate the cyst with careful root curettage to minimize injury, thereby preserving the vitality of the tooth. Furthermore, a histopathological results confirmed the diagnosis of a dentigerous cyst, which has a low recurrence rate (20).

After the surgery, one concern is the potential for external inflammatory root resorption, as the surgical procedure may disrupt the blood supply to the root apex, along with the loss of the protective layer on the root surface due to cystic wall curettage. Therefore, follow-up is crucial . If signs of endodontic disease are observed, root canal treatment should be initiated to eliminate the infection. On the other hand, in cases where the root apex is clearly compromised by the surgical procedure, such as when the root apex is exposed outside the bone, root canal treatment should be initiated within 10-14 days. This approach follows the same philosophy as treating mature avulsed teeth to prevent potential external inflammatory root resorption, which would be beneficial for the patient.

In tooth 11, the surgeon could not ensure that the blood supply was disrupted during the procedure, so a follow-up plan was established. However, the extent of the large cystic lesion and its close relationship with the adjacent tooth, the cyst removal process may damage or impair the nerve

and blood supply around the root apex of 21. Tooth 21 showed negative response to sensibility tests, and positive response to both percussion and palpation tests, suggesting that the apical inflammation may originate from pulp diseases.

Normally, any tooth that shows a negative response to sensibility test is usually indicated for root canal treatment, except in cases involving immature teeth, recently traumatized teeth, or teeth that have undergone surgical procedure that may involve the root apieces. These types of teeth require additional signs of necrosis to initiate root canal treatment. If the tooth is suspected to be necrosis, a cavity test should be performed. The cavity test is a sensibility test used to confirm the necrosis of the pulp in the teeth where the results of other sensibility tests may be questionable or impossible to obtain. The patient was advised to inform the dentist if they felt any sensitivity or pain during the procedure, then access was gradually drilled without local anesthesia. If patient had any feeling, the drill procedure would be stopped, and the cavity would be restored with appropriate material. If not, the necrotic pulp is confirmed, the root canal treatment procedure would continue.

In this case, root canal treatment of tooth 11 is suggested if signs of endodontic disease are present, beyond just a negative response to sensibility tests (for example, periapical radiolucency, dark discoloration of the tooth, soft tissue swelling or sinus tract opening). Therefore, a follow-up appointment for sensibility testing and evaluation of clinical symptoms is recommended after surgical procedures, as late recovery of sensibility response may occur.

In some cases of root canal treatment, external pressure resorption involving the root apex area may alter the position of root canal opening. The use of an electronic apex locator is important due to its capability to accurately locate the true opening of the root canal. Working length determination without using an electronic apex locator may result in overfilled obturation, even if a perfect length is displayed on the periapical radiograph.

For medication, some types of root resorption may require long-term medication with calcium hydroxide (e.g. external inflammatory root resorption) (21). However, for external pressure resorption, the cause is related to pressure generated by external stimuli. This type of resorption is not associated with infection inside the root canal, as is the case with external inflammatory root resorption; therefore, long term medication is not needed for external pressure resorption.

The appropriate timing for root canal filling in teeth with this type of root resorption is when the patient is symptom-free, the cause of pressure is removed, and the root canal is dry and free of pus (22).

Eventually, the management of teeth with external surface resorption associated with a certain origin requires an interdisciplinary approach that involves the dental specialties related to the underlying cause. Accurate diagnosis and periodic follow-up are recommended to identify the correct cause of the defect, prevention overtreatment, and achieve appropriate management for each case.

Conclusion

Dentigerous cyst may contribute to external pressure resorption of the neighboring tooth. Surgical removal of the embedded or impacted tooth and cystic tissue can compromise the nerve and blood supplies of the apices. Follow-up appointment for sensibility testing and evaluation of clinical symptoms is recommended to determine the necessity for endodontic intervention on the affected tooth. Thorough understanding of the biological principle of root resorption is essential for developing a correct treatment plan.

References

1. Endodontists AAo. Glossary of Endodontic Terms https://www.aae.org/specialty/clinical-resources/glossary-endodontic-terms/2020 [
2. Gunraj MN. Dental root resorption. Oral Surg Oral Med Oral Pathol Oral Radiol Endod. 1999;88(6):647-53.
3. Wedenberg C. Evidence for a dentin-derived inhibitor of macrophage spreading. Scand J Dent Res. 1987;95(5):381-8.
4. Wedenberg C, Lindskog S. Evidence for a resorption inhibitor in dentin. Scand J Dent Res. 1987;95(3):205-11.
5. Abbott PV, Lin S. Tooth resorption—Part 2: A clinical classification. Dental Traumatology. 2022;38(4):267-85.
6. Bourguignon C, Cohenca N, Lauridsen E, Flores MT, O'Connell AC, Day PF, et al. International Association of Dental Traumatology guidelines for the management of traumatic dental injuries: 1. Fractures and luxations. Dent Traumatol. 2020;36(4):314-30.
7. Endodontics Aao. The Recommended Guidelines of the American Association of Endodontists for The Treatment of Traumatic Dental Injuries. 2013.
8. Patel S, Krastl G, Weiger R, Lambrechts P, Tjäderhane L, Gambarini G, et al. ESE position statement on root resorption. Int Endod J. 2023;56(7):792-801.
9. Colak C, Aras B, Cheng LL, Elekdag-Turk S, Turk T, Darendeliler MA. Effects of rapid and slow maxillary expansion on root resorption: a micro-computed tomography study. Eur J Orthod. 2021;43(6):682-9.
10. Feller L, Khammissa RA, Thomadakis G, Fourie J, Lemmer J. Apical External Root Resorption and Repair in Orthodontic Tooth Movement: Biological Events. Biomed Res Int. 2016; 2016:4864195.
11. Kimura R, Anan H, Matsumoto A, Noda D, Maeda K. Dental root resorption and repair: histology and histometry during physiological drift of rat molars. J Periodontal Res. 2003;38(5):525-32.
12. Teo KW, Shi AH, Teh LY, Lee AMH. External root resorption in common odontogenic cysts and ameloblastomas of the jaw: A retrospective radiographic study in an Asian population. Oral Surgery. 2021;14(4):335-41.
13. Andreasen JO. External root resorption: its implication in dental traumatology, paedodontics, periodontics, orthodontics and endodontics. Int Endod J. 1985;18(2):109-18.
14. Andreasen JO, Hjorting-Hansen E. Replantation of teeth. I. Radiographic and clinical study of 110 human teeth replanted after accidental loss. Acta Odontol Scand. 1966;24(3):263-86.

15. Andreasen JO, Hjorting-Hansen E. Replantation of teeth. II. Histological study of 22 replanted anterior teeth in humans. Acta Odontol Scand. 1966;24(3):287-306.
16. Tronstad L. Root resorption--etiology, terminology and clinical manifestations. Endod Dent Traumatol. 1988;4(6):241-52.
17. Alharbi MA, Alghamdi A, Kattan SA, Austah O, Othman B, Haddad S, et al. The Incidence of Devitalization of Vital Teeth Associated with Pathologies of the Jaws Following Surgical Intervention: A Mixed-case Study. J Contemp Dent Pract. 2023;24(10):750-6.
18. Cardoso Tarallo AM, de Souza Matos F, Ferreira de Souza V, Renato Paranhos L, Moreira Herval Á, Carneiro Valera M, et al. Odontogenic Keratocyst: A Case Report Emphasizing on Root Canal Treatment after Surgical Intervention. Iran Endod J. 2019;14(2):160-5.
19. Ramana Reddy BV, Kiran Kumar K, Rajendra Santosh AB. Benign and Malignant Lesions of Jaw. Dent Clin North Am. 2020;64(1):39-61.
20. Ruslin M, van Trikt KN, Yusuf AS, Tajrin A, Fauzi A, Rasul MI, et al. Epidemiology, treatment, and recurrence of odontogenic and non-odontogenic cysts in South Sulawesi, Indonesia: A 6-year retrospective study. J Clin Exp Dent. 2022;14(3):e247-e53.
21. Trope M, Moshonov J, Nissan R, Buxt P, Yesilsoy C. Short vs. long-term calcium hydroxide treatment of established inflammatory root resorption in replanted dog teeth. Endod Dent Traumatol. 1995;11(3):124-8.
22. Abbott P. Prevention and management of external inflammatory resorption following trauma to teeth. Australian Dental Journal. 2016;61(S1):82-94.