Volume 4(1) January - June 2025

Thai Endodontic Journal (ENDOSARN)
วารสารเอ็นโดดอนติกส์ไทย (เอ็นโดสาร)

The official journal of the Thai Endodontic Association

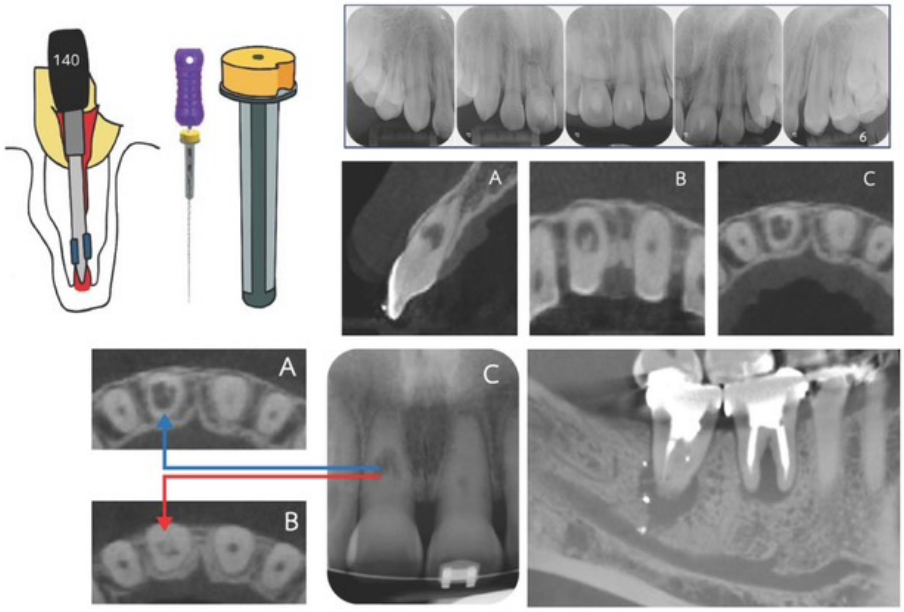

Interesting articles

- *Electronic Apex Locator: Principles, Evolution, Comparative Analysis, and Clinical Applications in Endodontics*
- *Extrusion of bioceramic-based root canal sealers into the inferior alveolar canal: A review of literature*
- *Regenerative endodontic procedures for avulsed immature permanent tooth with severe external root resorption*
- *การรักษาคลองรากฟันที่มีการละลายภายในคลองรากฟันแบบแทนที่*

Text and Journal Publication Co., LTD.

ISSN 1685-3709

Extrusion of calcium silicate-based root canal sealers into the inferior alveolar canal: A review of literature

Kitichai Singharat

Pakit Tungsawat

Division of Endodontics, College of Dental Medicine, Rangsit University

Abstract

Calcium silicate-based root canal sealers (CSS) have transformed root canal treatment with their excellent properties. However, the risk of extrusion into the inferior alveolar canal (IAC) may lead to nerve injuries and significant morbidity. Multiple factors contribute to extrusion, including anatomical variability, over-aggressive canal preparation, and the high flowability of CSS. Both non-surgical and surgical management strategies are discussed. Non-surgical interventions, including those that employ corticosteroids, B vitamins, and analgesics, show promise in reducing inflammation and supporting nerve recovery. In contrast, surgical techniques, including material removal and nerve decompression, are reserved for severe cases. Early diagnosis through advanced imaging, such as cone-beam computed tomography (CBCT), is crucial for effective intervention. Clinicians should conduct thorough preoperative assessments and refine obturation methods to minimize extrusion risks. Further research and the development of standardized guidelines are necessary to manage sealer extrusion into the IAC, which will enhance endodontic practice and minimize the risk of permanent nerve damage.

Keywords: apical extrusion, bioceramic root canal sealers, calcium silicate-based sealers, inferior alveolar canal, inferior alveolar nerve, mandibular canal

Correspondence: Pakit Tungsawat

College of Dental Medicine, Rangsit University, 52/347 Muang-Ake, Phaholyothin Road, Lak-Hok, Muang, Pathum Thani 12000 Thailand.

โทรศัพท์: 0-2997-2200-30 #4312

Email address: pakit.tu@rsu.ac.th

Received: 12 April 2025 **Revised:** 6 June 2025 **Accepted:** 13 June 2025

Introduction

The mandibular or inferior alveolar canal (IAC) is located beneath the apex of the mandibular posterior teeth. The anatomical relationship of the IAC, containing the inferior alveolar nerve (IAN) and artery, to the root apices of mandibular posterior teeth is an essential concern in root canal treatment. During both surgical and nonsurgical procedures, including local anesthetic, working length determination, mechanical instrumentation, root canal obturation, and apical surgery, IAN is at risk of damage due to its proximity. The results of the IAN injury are sensory disturbances, including anesthesia, paresthesia, and pain (1–3). This relationship has been studied using cone beam computed tomography (CBCT), which shows that the apices of mandibular second molars are often closer to IAC than those of first molars and premolars, with the distal root sometimes being the nearest (4). Anatomical knowledge and awareness of the IAC and apex relationship are essential in reducing the potential for iatrogenic nerve injury during endodontic treatment.

Root canal filling techniques have changed dramatically with the introduction of Calcium silicate-based root canal sealers (CSSs) (5). Unlike traditional root canal sealers, CSSs are hydrophilic, biocompatible, and exhibit high alkalinity during the setting process. Their superior flowability and slight expansion upon setting make them well-suited for use with the single-cone obturation technique (6). Even with the single-cone obturation technique, the efficacy of sealing and clinical outcomes remains comparable to those of traditional sealers using gutta-percha compacted obturation techniques (7–11). Furthermore, when CSS is used in combination with gutta-percha cones impregnated with bioceramic particles, a hermetic seal can be achieved, which may reinforce the prepared root as a positive consequence (12). In addition, if the clinician prefers, gutta-percha compression methods such as cold lateral compaction or warm vertical compaction can also still be used with CSS (13). However, a notable drawback of using warm vertical compaction with CSS is that it may interfere with the setting time and reduce flowability. Consequently, a new generation of CSS has been developed specifically for compatibility with warm obturation techniques—namely, TotalFill BC Sealer HiFlow and EndoSequence BC Sealer HiFlow (14,15).

The goal of root canal obturation is to ensure a tight seal, which resists fluid leakage from the coronal and apical areas and seals dentinal tubules. The filling technique was developed to fill the space within the root canal system as much as possible while considering the risk of materials extruding into periapical tissues (16). Root canal obturation techniques that deliver larger volumes of sealer with high flowability can increase the likelihood of material extrusion into the periapical tissues. The retrospective study found that when root canals were filled with iRoot SP using sealer-based techniques, the prevalence of apical extrusion was as high as 96% (17). It has come to the attention that such occurrences may result in irritation of periapical structures, alteration or loss of nerve sensation, delayed healing, and potentially compromised treatment outcomes. In particular, root canal treatment was performed in mandibular posterior teeth where the root apex is close to the IAC. There are reports of the extrusion of CSS into IAC with various consequences, such as transient or

permanent paresthesia, neuropathic pain, and sensory disturbances (18). Although the use of CSS has been around for almost two decades, few studies have examined the effects of CSS overextension beyond the root into IAC. This literature review aims to compile current knowledge regarding the impact, management, and treatment outcomes of cases involving CSS extrusion into IAC.

Relationship between mandibular teeth and IAC

The IAC is the pathway for the artery, vein, and nerve bundles to supply the structure of the mandible (19). The IAN is a division of the mandibular nerve, originating from the trigeminal nerve, which traverses the foramen ovale at the skull's base and then enters the mandible through the mandibular foramen. The usual pathway of IAC is located inferiorly and lingually in relation to the roots of the mandibular posterior teeth, particularly the molars and premolars (Figure 1). The distance from the distal root apex of the mandibular second molar to the IAC was found to vary based on age, gender, and even the side of the mandible (20).

The mandibular second molars have a closer and more frequent relationship with the IAC than the mandibular first molars (20). CBCT studies in various populations, including Egyptians, Emiratis, and the United Kingdom (UK), have consistently demonstrated this finding (Table 1). In the Egyptian study, the apices of mandibular second molars were significantly closer to the IAC, with mesial roots generally exhibiting a shorter distance than distal roots (20). An Emirati study found the distal root of the mandibular second molar to be the closest to the IAC, with a mean distance of 2.06 ± 1.83 mm (4). Furthermore, a UK-based study revealed that in over 50% of mandibular second molar roots, the distance to the IAC was ≤3 mm (21).

The mandibular premolars generally have a greater distance from the IAC than the mandibular molars. In an Emirati subpopulation study, the mean distance between the root apex of the mandibular second premolar and the IAC was 4.02 ± 2.02 mm, more significant than the distances observed for the molar roots (4). Similarly, a study in central India reported a more significant average distance from the second premolar root apex to the IAC than the molars (22).

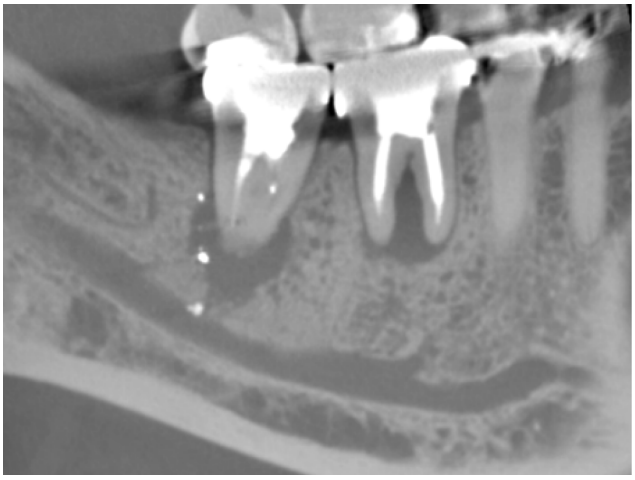

Figure 1 Relationship between IAC and mandibular first and second molars with small sealer extrusions into IAC

Factors affecting the distance between mandibular root apices and the IAC

Age, gender, anatomy, and tooth type all significantly influence the distance between mandibular root apices and the IAC (20). Younger patients tend to exhibit shorter distances, likely due to ongoing bone development, while older individuals generally show increased separation

because of continued bone growth and possible inferior canal migration (4,23). Gender differences are evident, with male subjects typically having greater distances than females, probably attributable to overall larger mandibular dimensions in men (24). Additionally, inherent anatomical variability, including differences in root morphology, the course of the IAC, and side-specific variations in cortical bone thickness, further contributes to the range of distances observed among individuals, underscoring the need for individualized radiographic assessment before invasive dental treatments (25). The proximity of root apices to the IAC is a critical factor influencing the risk of sealer extrusion and subsequent nerve injury.

Calcium silicate-based root canal sealers

Composition

CSS are characterized by their primary composition of calcium silicate-based materials, typically high concentrations of di- and tricalcium silicates (27). Additional compounds are introduced to modify the physico-chemical and biological characteristics of the substances. Common additives include radiopacifiers such as zirconium oxide and tantalite, facilitating radiograph visibility (28,29). Various thickening agents are also used to achieve the desired viscosity and handling properties. Different CSS consist of unique combinations of various components. For example, BioRoot Flow includes tricalcium silicate, calcium carbonate, zirconium oxide, propylene glycol, silica, and assorted polymers (27). TotalFill BC Sealer, iRoot SP, and EndoSequence BC Sealer include zirconium oxide, calcium silicates, calcium phosphate, and calcium hydroxide (29,30). AH Plus Bioceramic Sealer incorporates zirconium dioxide, tricalcium silicate, dimethyl sulfoxide, and lithium carbonate (27). Ceraseal and NeoSealer Flo utilize calcium silicates with radiopacifiers and potential additives like polyethylene glycol (31). Bio-C Sealer comprises calcium silicates, calcium aluminate, calcium oxide, zirconium oxide, and other inorganic components (32). Efforts continue to optimize CSS for better clinical performance.

Table 1 Studies of distances between root apices of mandibular teeth and the IAC

Author/Year	Population	Teeth	Mean distance (mm)
Oliveira et al., 2019 (26)	Brazilian	Left mandibular first premolar	5.76 ± 2.35
		Right mandibular first premolar	5.87 ± 2.44
		Left mandibular second premolar	3.97 ± 2.34
		Right mandibular second premolar	4.15 ± 2.47
Alazemi et al., 2024 (4)	Emirati	Mandibular second premolar	4.02 ± 2.02
Hiremath et al., 2016 (22)	Indian	Mandibular second premolar	4.09 ± 2.58
Sharaan et al., 2022 (20)	Egyptian	Mandibular first molar	2.11 - 3.95
Alazemi et al., 2024 (4)	Emirati	Mandibular second molar	2.06 ± 1.83
Chong et al., 2015 (21)	UK	Mandibular second molar (distal root)	2.70 ± 1.77
		Mandibular second molar (mesial root)	2.59 ± 1.38

Setting reaction

The setting or hardening of CSS is fundamentally a hydration-driven chemical process that occurs in the presence of moisture, which is typically sourced from the dentinal tubules and surrounding periapical tissues. This reaction primarily involves the hydration of the calcium silicate components, such as di- and tricalcium silicates, leading to the formation of a calcium silicate hydrate (CSH) gel and calcium hydroxide ($Ca(OH)_2$) (30). The generation of calcium hydroxide contributes to the high alkalinity of these sealers, which plays a role in their antibacterial properties. Furthermore, the interaction between the calcium-rich environment created by the hydrating sealer and the phosphate ions present in physiological fluids facilitates the precipitation of hydroxyapatite ($Ca_{10}(PO_4)_6(OH)_2$) at the interface of the sealer, which then bonds to the dentin wall (33).

Biological properties

CSS is gaining attention in endodontics due to its beneficial biological properties, which could improve treatment outcomes. CSS generally exhibits higher cell viability when compared to traditional epoxy resin-based sealers such as AH Plus (34). Studies show that BioRoot Flow and AH Plus Bioceramic Sealer have demonstrated significantly positive results in cytocompatibility assays with human periodontal ligament stem cells (hPDLSCs), unlike the less favorable outcomes seen with AH Plus (27). Similarly, EndoSequence BC Sealer formulations have shown comparable or superior biocompatibility (35). The interaction of CSS with hPDLSCs has been extensively studied due to the potential for sealer extrusion into the periodontal tissues. Studies consistently demonstrate that CSS exhibits adequate cytocompatibility, including cell metabolic activity, migration, and superior cell adhesion, compared to traditional sealers (36). However, several studies have reported no significant differences between CSS and AH Plus in terms of overall clinical outcomes (37–40).

CSS can interact with physiological fluids to induce hydroxyapatite formation. This biomineralization process improves the seal at the dentin-sealer interface and supports a suitable biological environment. Investigations have revealed that CSS stimulate the expression of genes associated with bone and cementum formation, including bone sialoprotein, cementum protein-1 (CEMP-1), and Cementum attachment protein (CAP) (27).

CSS have immunomodulatory effects in addition to interacting with cells and tissues. Studies have indicated that CSS can significantly reduce the production of pro-inflammatory cytokines such as IL-6 and IL-8 by hPDLSCs compared to epoxy resin-based sealers (27). This anti-inflammatory potential may help reduce post-operative inflammation and promote periapical healing.

The osteogenic and cementogenic potential of CSS is closely linked to their bioactivity. These materials can enhance the differentiation of stem cells towards osteoblasts and cementoblasts, which are critical cell types involved in hard tissue formation (41,42).

Although CSS are generally regarded as biocompatible and capable of promoting tissue regeneration, their extrusion into periapical tissues may still lead to adverse biological responses. When extruded beyond the apical foramen, CSS can induce local inflammation, cytotoxic effects, and mechanical irritation of the surrounding tissues. In vivo studies (43) have demonstrated that CSS

implanted in soft tissue elicited an inflammatory response characterized by infiltration of inflammatory cells and increased cytokine production. Furthermore, González-Martín et al. (2010) reported clinical cases where overextension of CSS resulted in periapical tissue irritation and subsequent nerve dysfunction (42).

Factors related to the cause of CSS extrusion

Sealer extrusion occurs when root canal sealer material is unintentionally pushed beyond the apical foramen of the root canal during a root canal obturation. It can occur due to a combination of factors related to anatomy, iatrogenic factors, delivery technique, and sealer properties. Few case reports of CSS extrusion into the IAC have been published (Table 2).

Anatomical Factors

Proximity of root apices to the IAC: The close relationship between the root tips of mandibular molars and the IAC increases the risk of sealer extrusion into the canal. The distance between the root apex and the IAC of the first molar can be varied. For the second molar, the distance is generally less than 1mm (47). The apices of the third molars are often very close to the alveolar nerve (5,48).

Mandibular bone density: Numerous cancellous bone in the mandible, particularly in the molar region, facilitate the spread of irrigating solutions and materials towards the inferior alveolar neurovascular bundle (49). A trabecular bone with a lower density and numerous lacunae may facilitate the penetration of extruded materials (50,51).

Periradicular lesions: Large periradicular lesions may increase the risk of extrusion (17,52). Endodontic infection and inflammation can weaken the bone barrier and cause the diffusion of materials.

Iatrogenic Factors

Over instrumentation: Excessive root canal preparation can lead to enlargement of the apical foramen and loss of constriction, which facilitates the extravasation of irrigating products or filling material beyond the apex.

Table 2 Reported Cases of CSS Extrusion into the IAC and associated neurological complications

Author/Year	Age/ Gender	Tooth	Sealer	Symptoms	Onset	Outcome
Alves et al., 2020 (46)	23 / F	47	MTA Fillapex	- Permanent labiomandibular paresthesia	Immediate	Persistent after 1 year
Stanley et al., 2023 (18)	27 / M	31	EndoSequence	- Paresthesia	Immediate	Resolved by 9 months
	59 / F	30	EndoSequence	- Paresthesia, - Dysesthesia, - Hyperalgesia		Persistent at 22 months
	23 / F	31	EndoSequence	- None	N/A	No symptoms

Incorrect working length: Overextension of cleaning and shaping beyond the apical foramen can directly contribute to sealer extrusion.

Sealer Delivery Techniques

Use of lentulo spiral or thermomechanical compaction: These techniques can increase the risk of extruding materials (53).

Lack of clinician experience: The dentist's skill in handling the materials and techniques can impact the likelihood of extrusion (18).

Back pressure: Back pressure can develop when the delivery tip fits tightly in the canal or when excessive force is applied during sealer placement. This may increase the risk of apical extrusion into the IAC, particularly in teeth with root apices located close to the IAC (18).

Hydraulic pressure: Even the passive introduction of the sealer, such as cold hydraulic or single cone technique, can cause extrusion due to hydraulic pressure (54).

Excessive vertical pressure: Excessive pressure during the compaction of filling materials may contribute to extrusion.

Notably, Jaha (2024) reported that the single-cone technique is associated with a significantly lower risk of sealer extrusion compared to warm vertical compaction (55).

Type of Sealer

The risk of extrusion varies among different types of sealers, with CSS exhibiting a higher incidence of extrusion compared to resin-based sealers, primarily due to their superior flowability (54). Zamparini et al. (2024) reported that premixed injectable bioceramic sealers exhibit higher flowability and lower viscosity compared to powder-liquid formulations, facilitating easier placement but also increasing the potential risk of apical extrusion, particularly when warm obturation techniques are employed. In contrast, powder-liquid bioceramic sealers, due to their higher viscosity, allow for more controlled application and thereby reduce the likelihood of extrusion. Meta-analysis revealed a wide range of extrusion rates for premixed bioceramic sealers (11.8% to 59.8%) compared to controls (11.8% to 33.3%) (56).

Nerve response to calcium silicate materials

Physical pressure (mechanical injury)

Extrusion of root canal filling material into the IAC can cause mechanical injury to the IAN through physical compression (44,57). The presence of extruded material within the canal can exert pressure on the nerve fibers, even without direct contact, leading to various neurosensory alterations (18). This mechanical compression may disrupt normal nerve conduction, manifesting as anesthesia (loss of sensation), hypoesthesia (reduced sensation), hyperesthesia (increased sensitivity), dysesthesia (unpleasant abnormal sensation), or paresthesia (2). The degree of damage depends on the amount of material extruded and the hydraulic or back pressure applied during obturation (58). In particular, when CSS spreads in a plasma-like pattern within the bone marrow or along the IAC, it can surround the neurovascular bundle and increase the likelihood of persistent symptoms (44,45).

Chemical components (cytotoxicity and inflammatory response)

In addition to mechanical effects, CSS extrusion can lead to chemical injury of the IAN due to the cytotoxicity and inflammatory potential of its components. The high alkalinity, ion release, and bioactivity of calcium silicate materials can trigger an inflammatory response in the surrounding tissues. Silva et al. reported that although both epoxy resin-based and CSS can elicit an initial inflammatory reaction, this response tends to resolve more rapidly with CSS, potentially resulting in a more favorable biological outcome in cases of extrusion (59). However, in vivo studies have shown that extruded CSS can still induce neurogenic inflammation by stimulating the release of neuropeptides, such as calcitonin gene-related peptide, from nociceptors (43). This process may contribute to symptoms like paresthesia and neuropathic pain. Additionally, nerve fiber sprouting and activation of peripheral C nociceptors have been implicated in cases of prolonged dysesthesia, heat hyperalgesia, and mechanical allodynia associated with CSS extrusion (18, 41).

Diagnosis

When CSS extruded into the IAC, early diagnosis, prompt recognition of symptoms, and radiographic confirmation could lead to more effective management. Clinical evaluation involves a thorough medical history, assessment of symptoms, and clinical neurosensory tests to assess the extent and severity of paresthesia. These tests can include mechanoceptive and nociceptive testing. Some patients may not experience any neurosensory deficits despite the extrusion of CSS into the IAC.

Radiographic evaluation involves periapical radiographs to determine the relationship between the root apex and nerve endings. However, conventional radiographs offer limited information. CBCT is recommended for a detailed three-dimensional view of the tooth, root canal, and surrounding tissues, which helps to determine the location of extruded materials and their proximity to the IAN (25). The radiograph can sometimes present a "plasma-like spreading pattern," where the sealer extends along the IAC and surrounds the neurovascular bundle during the root canal obturation procedure (18).

Management

Treatment approaches vary, ranging from non-surgical to surgical intervention. The choice of treatment depends on factors such as the severity of symptoms, volume and the extent of extrusion, and the patient's preferences.

Non-Surgical Interventions:

- **Monitoring and Follow-up:** Regular follow-up visits are essential to monitor the patient's symptoms and the resorption of the extruded material. This may include mapping the area of neurosensory alteration and involve pinpointing the region of neurosensory alteration. This method is based on the assumption that the cytotoxicity of sealers diminishes over time, particularly in patients exhibiting minor or absent symptoms or when the extruded material is a CSS, which could have superior biocompatibility (18).
- **Pharmacological Management:**
  - **Corticosteroids:** These may be used to decrease periapical inflammation caused by the extruded material.

▪ Prednisone 40–60 mg/day orally for 5–7 days, followed by gradual tapering to reduce periapical inflammation and nerve edema (60).

◦ **B Vitamins:** Supplements like vitamin B complex (thiamine, pyridoxine, and cyanocobalamin) are often used to promote nerve regeneration and the development of the myelin sheath.

▪ Vitamin B1 (Thiamine) 100 mg/day, Vitamin B6 (Pyridoxine) 100 mg/day.

▪ Vitamin B12 (Cyanocobalamin) 500–1000 mcg/day, Typically administered orally for 2–4 weeks (46,61).

◦ **Analgesics:** Pain medication may be prescribed to manage any discomfort.

▪ Ibuprofen 400–600 mg every 6–8 hours as needed for pain control.

▪ Alternatively, Acetaminophen 500–1000 mg every 6–8 hours may be used if NSAIDs are contraindicated (62).

◦ **Pregabalin (GABA analogue):** This can manage neuropathic pain associated with IAN injury. A case report showed the resolution of pain and paresthesia after non-surgical management, including prednisone and pregabalin. Another case also reported complete resolution of paraesthesia and pain with this combination therapy.

▪ Starting dose 75 mg twice daily (150 mg/day), titrated to 150–300 mg/day depending on patient tolerance and symptom control (58,63).

Outcomes of Non-Surgical Interventions:

The outcomes of conservative management vary and can be broadly categorized as favorable or unfavorable. Favorable outcomes refer to cases where neurosensory symptoms fully resolve or no symptoms occur despite confirmed sealer extrusion. For instance, Stanley et al. (2023) reported a case of temporary paresthesia that completely resolved within nine months following non-surgical management (18). In contrast, unfavorable outcomes involve persistent symptoms such as paresthesia, dysesthesia, or mechanical allodynia. For example, Alves et al. (2020) documented a case of permanent labiomandibular paresthesia persisting at one-year follow-up after MTA-based sealer extrusion, despite corticosteroid and vitamin B therapy (46). Clinical outcomes can range from complete resolution of symptoms (pain, paresthesia, anesthesia) to persistent or unchanged deficits. Prognosis is influenced by several factors, including the type and volume of extruded material, the chemical properties of the sealer, the location and proximity of the extrusion to the nerve, and the duration of nerve involvement, with prolonged compression generally associated with poorer outcomes.

Surgical Interventions:

Surgical interventions commonly used to manage extruded materials into the IAC include surgical removal, nerve decompression, and irrigation procedures with saline solution, as reported in several clinical studies (56,60). Surgical methods are sometimes necessary to fully recover sensation. However, surgical procedures can also increase the risk of additional nerve damage. Surgical removal of extruded material is often recommended, especially when dealing with larger extrusions, neurotoxic materials, or persistent symptoms. The primary objective is completely removing the foreign body to relieve symptoms and prevent further complications. Nerve decompression involves releasing the IAN from compression by removing surrounding bone or restrictive tissues.

A range of techniques are used, such as lateral window opening, which allows access to the IAN via a lateral approach (Figure 2). Sagittal split osteotomy, a more invasive surgical procedure that is occasionally used to improve nerve access and decompression. Additionally, irrigation of the IAC is often performed intraoperatively to assist in thoroughly removing the extruded material and minimizing residual contamination (64,65).

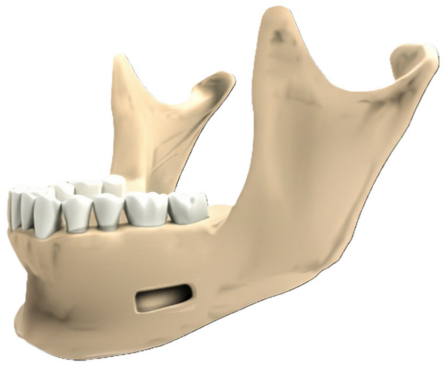

Figure 2 Lateral window opening approach for surgical access to the IAC.

Outcomes of Surgical Interventions:

Surgical interventions often result in notable improvements in neurosensory function, including reductions or resolution of paresthesia, anesthesia, dysesthesia, and associated pain. Early intervention typically yields a more favorable prognosis (61). Nevertheless, even after three weeks or longer, delayed surgery can still significantly improve sensory recovery (53). However, the extent of recovery varies among individuals, and while some patients experience dramatic or complete restoration of normal sensation, others may achieve only moderate to substantial improvements. Microsurgical techniques have demonstrated beneficial outcomes in addressing neurosensory deficits associated with endodontic treatments (66). Despite these positive findings, in cases of extensive or prolonged nerve damage, surgical outcomes become less predictable, and complete recovery might not always be attainable (65).

Factors influencing the selection of treatment options

Several factors influence the choice of treatment (Figure 3) in cases of material extrusion into the IAC. The severity of symptoms significantly guides the therapeutic approach, with mild symptoms often managed conservatively, whereas severe or persistent symptoms typically necessitate surgical intervention. Additionally, the amount and neurotoxicity of the extruded sealer play critical roles, as larger quantities of extruded materials, particularly those with high neurotoxicity, may require surgical removal (46,60,64). Ruparel et al. 2014 demonstrated that AH Plus exhibited greater neurotoxicity by significantly increasing CGRP release, whereas EndoSequence BC Sealer showed minimal to no neurotoxic effect (68). The exact location of the extrusion, especially its proximity to the nerve or presence within the IAC, also strongly influences treatment decisions. The timing of intervention is crucial; early surgical intervention generally leads to better clinical outcomes, although delayed procedures can still yield considerable improvement (65). Some clinicians advocate for immediate surgical intervention for nerve injuries, as early repairs are thought to be more successful than delayed ones, but this is still controversial (49). Finally, patient preference is essential, as some individuals might initially favor conservative management (18). In contrast, others, upon being informed about the associated risks, benefits, and alternatives, might prefer immediate surgical intervention (53).

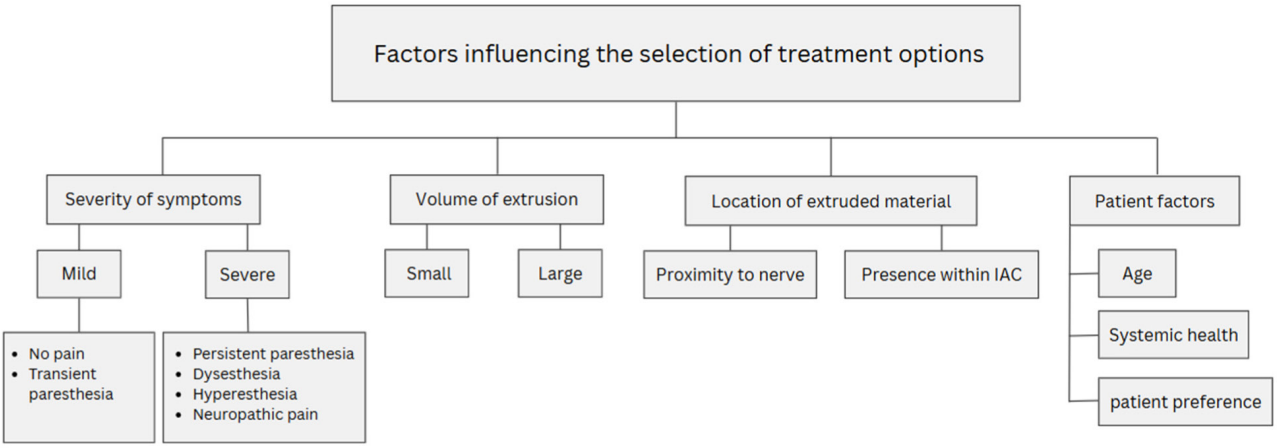

Figure 3 Factors influencing the selection of treatment options

Recovery patterns and Prognosis

The recovery duration from neurosensory alterations caused by sealer extrusion into the IAC varies, with some cases resolving quickly and others persisting for an extended period. These can be categorized into four groups.

Temporary paresthesia: This may be resolved spontaneously within a few months, and in some cases, it can be resolved even earlier. One report documented complete recovery within nine months following the extrusion of CSS, despite its favorable biocompatibility. Several factors may contribute to the development of paresthesia, including the injection technique, volume of extruded material, host inflammatory response, and anatomical variations (18). In contrast, another case involving AH Plus showed symptom improvement within a few days and complete resolution within one month. This favorable outcome was likely influenced by the relatively small volume of extruded material and early pharmacologic intervention with pregabalin and prednisone to manage neurogenic pain and paresthesia (58).

Partial Resolution: Some patients may experience reduced symptoms but do not completely recover. In one case, a patient experienced decreased paresthesia intensity and a return of temperature sensation, but the affected area remained the same after 3 months. Another case of CSS reported that the "pins and needles" sensation persisted, though tenderness in the gingiva and mucosa resolved (18). One patient reported a gradual reduction in paresthesia over two weeks and a complete resolution within one month.

Permanent Paresthesia: Paresthesia is considered permanent when it lasts longer than 6 months (47,69). Using CSS, one case describes a patient experiencing paresthesia that persisted for one year with little change in the affected area and was considered permanent (46). Another case reported persistent paresthesia, hyperalgesia, and mechanical allodynia at 22 months (18). This can affect a patient's quality of life, such as eating, drinking, speaking, and making them uncomfortable.

No Neurosensory Alteration: Some patients experience no neurosensory deficits despite sealer extrusion into the IAC (18).

Prevention

Thorough preoperative radiographic examinations, including panoramic radiographs and potentially CBCT when a close relationship is suspected, are essential to accurately assess the proximity of root apices, particularly those of mandibular molars and premolars, to the IAC (50,65). This assessment helps in identifying potential risks of IAN injury during endodontic procedures. To prevent material extrusion, it is crucial to establish the proper working length using both electronic apex locators and radiographic confirmation, ensuring that instrumentation remains within the confines of the root canal. Clinicians should avoid over-instrumentation with hand or engine-driven files beyond the apical foramen and prevent excessive widening of the apical foramen, as this can lead to the disappearance of apical constriction and facilitate the passage of materials beyond the apex. During the delivery of CSS or other filling materials, active pressure should be avoided (18). Techniques such as cold hydraulic or sealer-based obturation methods, including cold lateral compaction, are recommended as they have proven more effective in preventing overextension of dental filling materials than techniques like warm vertical compaction or using lentulo spirals. Clinicians must always be aware of the potential risks of mechanical and chemical injury to the IAN when the root apex is close to the IAC. The anatomy of IAN and its varying relationship with molar root apices, including direct contact, highlights the importance of accurate technique and thorough radiographic evaluation (Table 3).

Conclusions

The extrusion of CSS into the IAC poses a significant clinical challenge with unpredictable recovery outcomes. Current management approaches, ranging from conservative pharmacological interventions to invasive surgical procedures, demonstrate variable efficacy in addressing neurosensory complications. Despite advancements in endodontic techniques and material biocompatibility, the inconsistency of treatment results underscores the need to develop standardized management guidelines. Comprehensive protocols should consider factors such as anatomical variations, extent of extrusion, sealer properties, and timing of intervention. Such guidelines would facilitate more predictable outcomes and improve patient safety, ensuring clinicians have clear, evidence-based pathways to follow when managing CSS extrusion. Ultimately, prevention remains the most effective strategy for

Table 3 Prevention methods for sealers' extrusion into the IAC.

Procedure	Prevention methods
Preoperative Assessment	Panoramic radiographs and/or CBCT when root apex proximity is suspected
Working Length Determination	Use an electronic apex locator with radiographic confirmation
Mechanical instrumentation	Avoid over-instrumentation beyond the apical foramen
Obturation Technique	Prefer cold hydraulic, sealer-based, or cold lateral compaction
Sealer Delivery	Avoid active pressure during CSS placement

avoiding IAN injury in high-risk cases. Careful preoperative assessment of root canal anatomy and its proximity to the IAC, the use of advanced imaging such as CBCT, controlled sealer delivery without excessive pressure, and strict adherence to proper obturation techniques are critical measures to minimize the risk of extrusion. Emphasizing prevention not only reduces the likelihood of neurosensory complications but also mitigates the need for unpredictable and potentially invasive interventions.

References

1. Chong BS, Gohil K, Pawar R, Makdissi J. Anatomical relationship between mental foramen, mandibular teeth and risk of nerve injury with endodontic treatment. **Clin Oral Investig.** 2017;21:381–7.
2. Castro R, Guivarc'h M, Foletti JM, Catherine JH, Chossegros C, Guyot L. Endodontic-related inferior alveolar nerve injuries: A review and a therapeutic flow chart. **J Stomatol Oral Maxillofac Surg.** 2018;119:412–8.
3. Reda R, Zanza A, Bhandi S, De Biase A, Testarelli L, Miccoli G. Surgical-anatomical evaluation of mandibular premolars by CBCT among the Italian population. **Dent Med Probl.** 2022;59:209–16.
4. Alazemi A, Muhairi EA, Alharbi N, Abdunabi F, Mashyakhy M, Chaudhry J, et al. Evaluation of Mental Foramen and Mandibular Canal Course and Location in an Emirati Subpopulation. **Int Dent J.** 2024;74:1142–50.
5. Wongwatanasanti N, Tungsawat P, Suksaphar W, Lertnantapanya S, Yodmanotham P. Root Canal Treatment and Demand for Continuing Education among Thai Dental Practitioners. **Open Dent J.** 2024;25;18:e18742106308012.
6. Chybowski EA, Glickman GN, Patel Y, Fleury A, Solomon E, He J. Clinical Outcome of Non-Surgical Root Canal Treatment Using a Single-cone Technique with Endosequence Bioceramic Sealer: A Retrospective Analysis. **J Endod.** 2018;44:941–5.
7. Tanompetsanga P, Tungsawat P. Microleakage in Immediate vs Delayed Post Space Preparation in Root Canals Filled with Bioceramic-based Root Canal Sealer. **World J Dent.** 2020;11:172–8.
8. Suksaphar W, Tungsawat P, Wongwatanasanti N, Lertnantapanya S, Yodmanothum P. Effect of Different Tapered Gutta-Percha Points on Push-Out Bond Strength of Two Root Canal Sealers. **Eur J Gen Dent.** 2025;27;s-0044-1800800.
9. Tanompetsanga P, Tungsawat P. Microleakage in Immediate vs Delayed Post Space Preparation in Root Canals Filled with Bioceramic-based Root Canal Sealer. **World J Dent.** 2020;11:172–8.
10. Chybowski EA, Glickman GN, Patel Y, Fleury A, Solomon E, He J. Clinical Outcome of Non-Surgical Root Canal Treatment Using a Single-cone Technique with Endosequence Bioceramic Sealer: A Retrospective Analysis. **J Endod.** 2018;44:941–5.
11. Zamparini F, Lenzi J, Duncan HF, Spinelli A, Gandolfi MG, Prati C. The efficacy of premixed bioceramic sealers versus standard sealers on root canal treatment outcome, extrusion rate and post-obturation pain: A systematic review and meta-analysis. **Int Endod J.** 2024;57:1021–42.

12. Osiri S, Banomyong D, Sattabanasuk V, Yanpiset K. Root Reinforcement after Obturation with Calcium Silicate–based Sealer and Modified Gutta-percha Cone. **J Endod.** 2018;44: 1843–8.
13. Dewi A, Upara C, Sastraruji T, Louwakul P. Effect of a heat-based root canal obturation technique on push-out bond strength of the classical bioceramic and new HiFlow sealer. **Aust Endod J.** 2022;48:116–20.
14. Alkahtany SM, AlHussain AA, AlMthen HA, AlDokhi HD, Bukhary SM, Almohaimede AA, et al. Obturation quality of bioceramic sealers with different obturation techniques: a micro-CT evaluation. **Sci Rep.** 2024;14:31146.
15. Mobayed M, Ayoubi HR, Achour H, Alsayed Tolibah Y. Comparison of Different Obturation Techniques in the Dentinal Tubule Penetration of EndoSequence® Bioceramic Sealer HiFlow™: An In-Vitro Study. **Cureus.** 2024;16:e71155.
16. Dasari L, Anwarullah A, Mandava J, Konagala R, Karumuri S, Chellapilla P. Influence of obturation technique on penetration depth and adaptation of a bioceramic root canal sealer. **J Conserv Dent.** 2020;23:505.
17. Li J, Chen L, Zeng C, Liu Y, Gong Q, Jiang H. Clinical outcome of bioceramic sealer iRoot SP extrusion in root canal treatment: a retrospective analysis. **Head Face Med.** 2022;18:28.
18. Stanley E, Strother KK, Kirkpatrick T, Jeong JW. Calcium Silicate–based Sealer Extrusion into the Mandibular Canal: 3 Different Recovery Outcomes—A Report of 3 Cases. **J Endod.** 2023;49:735–41.
19. Iwanaga J, Matsushita Y, Decater T, Ibaragi S, Tubbs RS. Mandibular canal vs. inferior alveolar canal: Evidence-based terminology analysis. **Clin Anat.** 2021;34:209–17.
20. Sharaan MES, Abdulla AY, Ragab MH. Assessment of the relationship of the distance between mandibular first and second molars with the inferior alveolar canal and cortical bone plate in an Egyptian subpopulation: a CBCT study. **Braz Oral Res.** 2022;36:e033.
21. Chong BS, Quinn A, Pawar RR, Makdissi J, Sidhu SK. The anatomical relationship between the roots of mandibular second molars and the inferior alveolar nerve. **Int Endod J.** 2015;48:549–55.
22. Hiremath H, Agarwal R, Hiremath V, Phulambrikar T. Evaluation of proximity of mandibular molars and second premolar to inferior alveolar nerve canal among central Indians: A cone-beam computed tomographic retrospective study. **Indian J Dent Res.** 2016;27:312.
23. Aqili TM, Almuzaini ES, Aljohani AS, Saeedi AKA, Hammudah HA, Alassaf M, et al. Evaluation of the variations of mandibular molars and the distance from root apex to the inferior alveolar nerve in Saudi Sub-population: Three-dimensional radiographic evaluation. Karobari MI, editor. **PLOS ONE.** 2025;20:e0317053.
24. Kawashima Y, Sakai O, Shosho D, Kaneda T, Gohel A. Proximity of the Mandibular Canal to Teeth and Cortical Bone. **J Endod.** 2016;42:221–4.
25. Do TT, Le LN, Tan LT, Dang ATT, Huynh DNK, Truong MH, et al. Investigating the characteristics of the mandibular canal in cone beam CT. **J Orthod Sci.** 2024;13:45:1–6.
26. Oliveira ACS, Candeiro GTM, Pacheco da Costa FFN, Gazzaneo ID, Alves FRF, Marques FV.

Distance and Bone Density between the Root Apex and the Mandibular Canal: A Cone-beam Study of 9202 Roots from a Brazilian Population. **J Endod.** 2019;45:538-542.e2.

27. Sanz JL, López-García S, García-Bernal D, Rodríguez-Lozano FJ, Forner L, Lozano A, et al. Comparative bioactivity and immunomodulatory potential of the new Bioroot Flow and AH Plus Bioceramic sealer: An in vitro study on hPDLSCs. **Clin Oral Investig.** 2024;28:195.
28. Sarunket C, Banomyong D, Vibulcharoenkitja P, Sutimuntanakul S. Radiopacity of Portland cement and calcium silicate-based cement with different mixed ratios of radiopacifiers. **Eur Endod J.** 2022;7:52–7.
29. Sanz JL, López-García S, Rodríguez-Lozano FJ, Melo M, Lozano A, Llena C, et al. Cytocompatibility and bioactive potential of AH Plus Bioceramic Sealer: An *in vitro* study. **Int Endod J.** 2022;55:1066–80.
30. Lim M, Jung C, Shin DH, Cho Y bum, Song M. Calcium silicate-based root canal sealers: a literature review. **Restor Dent Endod.** 2020;45:e35.
31. Zamparini F, Prati C, Taddei P, Spinelli A, Di Foggia M, Gandolfi MG. Chemical-physical properties and bioactivity of new premixed calcium silicate-bioceramic root canal sealers. **Int J Mol Sci.** 2022;23:13914.
32. Zordan-Bronzel CL, Esteves Torres FF, Tanomaru-Filho M, Chávez-Andrade GM, Bosso-Martelo R, Guerreiro-Tanomaru JM. Evaluation of physicochemical properties of a new calcium silicate–based sealer, Bio-C sealer. **J Endod.** 2019;45:1248–52.
33. Estivalet MS, De Araújo LP, Immich F, Da Silva AF, Ferreira NDS, Da Rosa WLDO, et al. Bioactivity potential of bioceramic-based root canal sealers: A scoping review. **Life.** 2022;12:1853.
34. Souza LCD, Neves GST, Kirkpatrick T, Letra A, Silva R. Physicochemical and biological properties of AH Plus bioceramic. **J Endod.** 2023;49:69–76.
35. Kwak SW, Koo J, Song M, Jang IH, Gambarini G, Kim HC. Physicochemical properties and biocompatibility of various bioceramic root canal sealers: In vitro study. **J Endod.** 2023;49:871–9.
36. Mora A, García-Bernal D, Rodríguez-Lozano FJ, Sanz JL, Forner L, Ghilotti J, et al. Biocompatibility, bioactivity and immunomodulatory properties of three calcium silicate-based sealers: an in vitro study on hPDLSCs. **Clin Oral Investig.** 2024;28:416.
37. Bamrungwong J, Ratisoontorn C, Hiran-Us S, Sinsareekul C. Outcomes and prognostic factors of endodontically treated teeth with unintentional root canal sealer extrusion: A retrospective cohort study. **J Dent.** 2025;158:105804.
38. Algar J, Docampo-Vázquez C, Rico-Romano C, Boquete-Castro A, Obispo-Díaz C, Aragoneses JM. Randomised Clinical Trial: Effect of AH Plus and Neosealer Flo on Postoperative Pain and Healing of Periapical Lesions. **Bioeng Basel Switz.** 2025;12:376.
39. Zamparini F, Spinelli A, Cardinali F, Ausiello P, Gandolfi MG, Prati C. The Use of Premixed Calcium Silicate Bioceramic Sealer with Warm Carrier-Based Technique: A 2-Year Study for Patients Treated in a Master Program. **J Funct Biomater.** 2023;14:164.

40. Kangseng T, Banomyong D, Osiri S, Jantarat J. Outcomes and prognostic factors of endodontically treated teeth filled with calcium silicate- or epoxy resin-based root canal sealers: A retrospective cohort study. **Int Endod J.** 2025;58:84–96.
41. López-García S, Sánchez-Bautista S, García-Bernal D, Lozano A, Forner L, Sanz JL, et al. Premixed calcium silicate-based ceramic sealers promote osteogenic/cementogenic differentiation of human periodontal ligament stem cells: A microscopy study. **Microsc Res Tech.** 2024;87:1584–97.
42. Sanz JL, Guerrero-Gironés J, Pecci-Lloret MP, Pecci-Lloret MR, Melo M. Biological interactions between calcium silicate-based endodontic biomaterials and periodontal ligament stem cells: A systematic review of *in vitro* studies. **Int Endod J.** 2021;54:2025–43.
43. Elias VV, Lima RB, Lucisano MP, Araujo LDC, Pucinelli CM, Nelson-Filho P, et al. Inflammatory response to bioceramic and epoxy resin-based endodontic sealers implanted in mice subcutaneous tissue: An in vivo study. **Microsc Res Tech.** 2024;87:2447–58.
44. González-Martín M, Torres-Lagares D, Gutiérrez-Pérez JL, Segura-Egea JJ. Inferior alveolar nerve paresthesia after overfilling of endodontic sealer into the mandibular canal. **J Endod.** 2010;36:1419–21.
45. Mahmood H, Hoare J, Atkins S. Chemical neurotoxicity to the inferior alveolar nerve—A rare sequela of endodontic treatment. **Oral Surg.** 2022;15:663–8.
46. Alves FRF, Dias MCC, Mansa MGCB, Machado MD. Permanent Labiomandibular Paresthesia after Bioceramic Sealer Extrusion: A Case Report. **J Endod.** 2020;46:301–6.
47. Tilotta-Yasukawa F, Millot S, El Haddioui A, Bravetti P, Gaudy JF. Labiomandibular paresthesia caused by endodontic treatment: an anatomic and clinical study. **Oral Surg Oral Med Oral Pathol Oral Radiol Endodontology.** 2006;102:e47–59.
48. Denio D, Torabinejad M, Bakland LK. Anatomical relationship of the mandibular canal to its surrounding structures in mature mandibles. **J Endod.** 1992;18:161–5.
49. Alves FR, Coutinho MS, Gonçalves LS. Endodontic-related facial paresthesia: systematic review. **J Can Dent Assoc.** 2014;80:e13.
50. Oliveira ACS, Candeiro GTM, Pacheco Da Costa FFN, Gazzaneo ID, Alves FRF, Marques FV. Distance and bone density between the root apex and the mandibular canal: A cone-beam study of 9202 roots from a Brazilian population. **J Endod.** 2019;45:538-542.e2.
51. Başa O, Dilek OC. Assessment of the risk of perforation of the mandibular canal by implant drill using density and thickness parameters: Assessment of the risk of perforation of the mandibular canal. **Gerodontology.** 2011;28:213–20.
52. Martins JFB, Scheeren B, Van Der Waal SV. The effect of unintentional AH-Plus sealer extrusion on resolution of apical periodontitis after root canal treatment and retreatment—A retrospective case-control study. **J Endod.** 2023;49:1262–8.
53. Bastien AV, Adnot J, Moizan H, Calenda É, Trost O. Secondary surgical decompression of the inferior alveolar nerve after overfilling of

endodontic sealer into the mandibular canal: Case report and literature review. **J Stomatol Oral Maxillofac Surg.** 2017;118:389–92.

54. Fonseca B, Coelho MS, Bueno CEDS, Fontana CE, Martin ASD, Rocha DGP. Assessment of extrusion and postoperative pain of a bioceramic and resin-based root canal sealer. **Eur J Dent.** 2019;13:343–8.
55. Jaha HS. Hydraulic (Single Cone) Versus Thermogenic (Warm Vertical Compaction) Obturation Techniques: A Systematic Review. **Cureus.** 2024;16:e62925.
56. Zamparini F, Lenzi J, Duncan HF, Spinelli A, Gandolfi MG, Prati C. The efficacy of premixed bioceramic sealers versus standard sealers on root canal treatment outcome, extrusion rate and post-obturation pain: A systematic review and meta-analysis. **Int Endod J.** 2024;57:1021–42.
57. Deniz-Sungur D, Onur MA, Akbay E, Tan G, Daglı-Comert F, Sayın TC. Effects of calcium silicate cements on neuronal conductivity. **Restor Dent Endod.** 2022;47:e18.
58. López-López J, Estrugo-Devesa A, Jané-Salas E, Segura-Egea JJ. Inferior alveolar nerve injury resulting from overextension of an endodontic sealer: non-surgical management using the GABA analogue pregabalin. **Int Endod J.** 2012;45:98–104.
59. Alves Silva EC, Tanomaru-Filho M, da Silva GF, Delfino MM, Cerri PS, Guerreiro-Tanomaru JM. Biocompatibility and Bioactive Potential of New Calcium Silicate-based Endodontic Sealers: Bio-C Sealer and Sealer Plus BC. **J Endod.** 2020;46:1470–7.
60. Scarano A, Di Carlo F, Quaranta A, Piattelli A. Injury of the inferior alveolar nerve after overfilling of the root canal with endodontic cement: a case report. **Oral Surg Oral Med Oral Pathol Oral Radiol Endodontology.** 2007;104:e56–9.
61. Köseog˘lu BG, Tanrıkulu Ş, Sübay RK, Sencer S. Anesthesia following overfilling of a root canal sealer into the mandibular canal: A case report. **Oral Surg Oral Med Oral Pathol Oral Radiol Endodontology.** 2006;101:803–6.
62. Blanas N, Kienle F, Sàndor GKB. Injury to the inferior alveolar nerve due to thermoplastic gutta percha. **J Oral Maxillofac Surg.** 2002;60:574–6.
63. Alonso-Ezpeleta O, Martin Pj, Lopez-Lopez J, Castellanos-Cosano L, Martin-Gonzalez J, Segura-Egea Jj. Pregabalin in the treatment of inferior alveolar nerve paraesthesia following overfilling of endodontic sealer. **J Clin Exp Dent.** 2014;e197-202.
64. Scolozzi P, Lombardi T, Jaques B. Successful inferior alveolar nerve decompression for dysesthesia following endodontic treatment: report of 4 cases treated by mandibular sagittal osteotomy. **Oral Surg Oral Med Oral Pathol Oral Radiol Endod.** 2004;97:625–31.
65. Kim JE, Cho JB, Yi WJ, Heo MS, Lee SS, Choi SC, et al. Accidental overextension of endodontic filling material in patients with neurologic complications: a retrospective case series. **Dentomaxillofac Radiol.** 2016;45:20150394.
66. Management of endodontic injuries to the inferior alveolar nerve. **Quintessence Int.** 2016;47:581–7.

67. Byun S -H., Kim S -S., Chung H -J., Lim H -K., Hei W -H., Woo J -M., et al. Surgical management of damaged inferior alveolar nerve caused by endodontic overfilling of calcium hydroxide paste. **Int Endod J.** 2016;49:1020–9.
68. Ruparel NB, Ruparel SB, Chen PB, Ishikawa B, Diogenes A. Direct effect of endodontic sealers on trigeminal neuronal activity. **J Endod.** 2014;40:683–7.
69. Schultze-Mosgau S, Reich RH. Assessment of inferior alveolar and lingual nerve disturbances after dentoalveolar surgery, and of recovery of sensitivity. **Int J Oral Maxillofac Surg.** 199;22:214–7.