Volume 5(1) January - June 2026

TEJ

Thai Endodontic Journal (ENDOSARN)
วารสารเอ็นโดดอนติกส์ไทย (เอ็นโดสาร)

The official journal of the Thai Endodontic Association

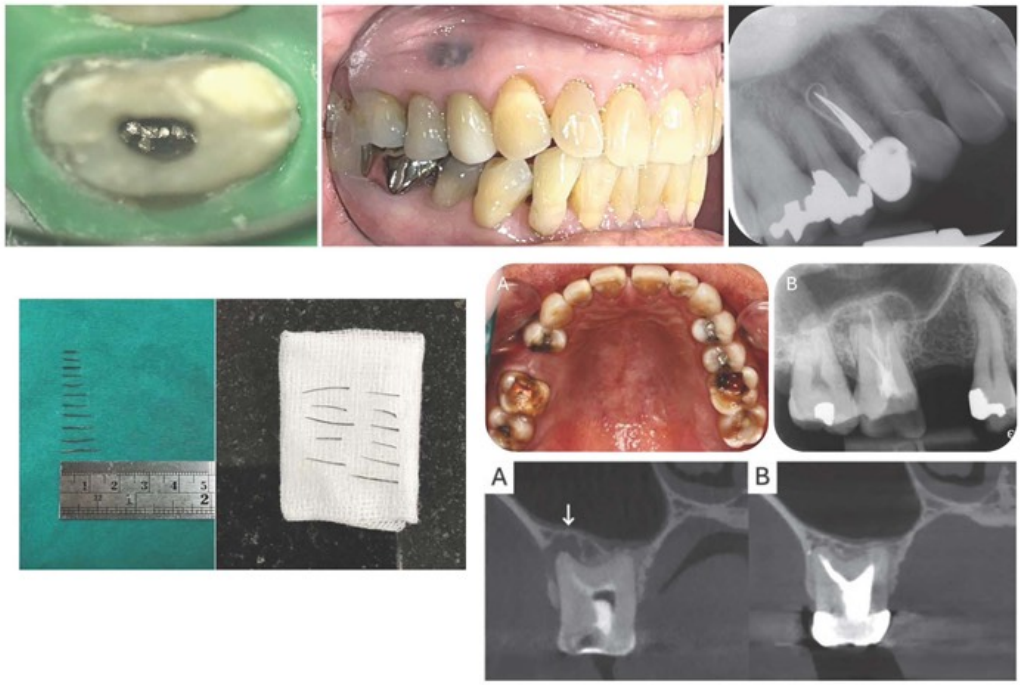

Interesting articles

- ***Non-surgical Retreatment of a Taurodont Molar with Maxillary Sinusitis of Endodontic Origin: A Case Report***
- ***Non-surgical root canal retreatment: a case report of eleven silver cones removal in maxillary first premolar***
- ***Minimal invasive endodontics: A comprehensive review on access preparation and mechanical instrumentation strategies - Part I: access cavity design***

Text and Journal Publication Co., LTD.

ISSN 1685-3709

Non-surgical Retreatment of a Taurodont Molar with Maxillary Sinusitis of Endodontic Origin: A Case Report

Supitchaya Techachan, Tadkamol Krongbaramee, Anat Dewi

Department of Restorative Dentistry and Periodontology, Faculty of Dentistry, Chiang Mai University, Chiang Mai, Thailand

Abstract

Taurodontism is a dental anomaly characterized by an apically displaced pulpal floor and an elongated pulp chamber, which complicates root canal treatment due to its atypical root morphology. This case report presents the non-surgical root canal retreatment of a taurodont maxillary first molar with an additional mesiobuccal canal associated with maxillary sinusitis of endodontic origin (MSEO). A 57-year-old male patient presented with dull pain at tooth 16, which had previously undergone root canal therapy. Clinical examination revealed dislodgement restoration with gutta-percha exposure, tenderness to percussion, and radiographic evaluation demonstrated underfilled root canals with periapical radiolucencies around the mesiobuccal and distobuccal roots. Cone Beam Computed Tomography (CBCT) confirmed the taurodont morphology, suggested the presence of an additional canal, and revealed Periapical Osteoperiostitis (PAO). Under a dental operating microscope, all five canals (MB1, MB2, additional MB, DB, and P) were negotiated, cleaned, and shaped using rotary instrumentation and supplemental irrigation. Calcium hydroxide was placed as an intracanal medicament, and obturation was performed using a hydraulic condensation technique with a bioceramic sealer. The patient remained asymptomatic after retreatment, and 2-year follow-up radiographs demonstrated complete periapical and sinus healing. This case highlights the importance of CBCT and magnification in identifying complex root canal morphology and achieving favorable outcomes in the retreatment of taurodont teeth with MSEO.

Keywords: additional canal, maxillary molar, maxillary sinusitis, non-surgical retreatment, taurodontism

Correspondence: Anat Dewi

Department of Restorative Dentistry and Periodontology, Faculty of Dentistry, Chiang Mai University

Contact number: 053-944457

Email address: anatdewident@gmail.com

Received: 15 December 2025 **Revised:** 21 April 2026 **Accepted:** 24 April 2026

Introduction

Taurodontism, first described by Keith in 1913 (1), is a developmental anomaly characterized by an enlarged pulp chamber, absence of cervical constriction at the cementoenamel junction (CEJ), and apical displacement of the pulpal floor (1-5). This condition results from incomplete invagination of Hertwig's epithelial root sheath during development (2, 6, 7). The condition is classified by Shifman and Chanannel into hypo-, meso-, and hypertaurodont types based on the degree of apical displacement (8). Its prevalence varies widely among populations, ranging from 0.1% to 48%, and it most commonly affects maxillary molars, though premolars and primary teeth may also be involved (6).

Endodontic treatment of taurodont teeth is challenging due to atypical root morphology, including deep pulp chambers, apically positioned orifices, shortened roots, and possible presence of additional or accessory canals (6, 9). These variations increase the risk of missed anatomy or inadequate debridement. Modern diagnostic tools such as Cone Beam Computed Tomography (CBCT) and dental operating microscopes greatly improve the detection of complex canal systems (10, 11).

In the maxillary posterior region, persistent periapical infection may extend into the sinus, causing maxillary sinusitis of endodontic origin (MSEO) (12). Its presentation may be subtle, and differentiation from rhinogenic or non-endodontic odontogenic sinusitis requires imaging (12). Patients with MSEO may have a wide range of dental and sinonasal symptoms, and in some cases, patients may have no symptoms. CBCT is essential for identifying sinus involvement and distinguishing radiographic patterns such as periapical osteoperiostitis (PAO), seen as a reactive radiopaque "halo" and periapical mucositis (PAM), seen as localized mucosal thickening adjacent to the infected root (13-15). Management focuses on eliminating the dental source through appropriate endodontic therapy, with CBCT also valuable for follow-up (12).

Although taurodontism has been reported to complicate endodontic treatment because of its unusual root canal anatomy, there are limited reports describing non-surgical retreatment of maxillary taurodont molars associated with MSEO. Therefore, this case report aims to describe the non-surgical retreatment of a maxillary taurodont molar with a calcified additional canal associated with MSEO, emphasizing the role of advanced imaging and magnification in achieving successful outcomes.

Case Report

A 57-year-old male patient reported no systemic diseases and no known drug allergies. He presented with a chief complaint of dull pain in the upper right posterior region. The patient had undergone root canal treatment on tooth 16 ten years earlier. The coronal restoration had dislodged approximately one year ago. The patient experienced pain one to two weeks prior to the visit, prompting him to seek dental care.

Clinical and radiographic examinations

Extraoral examination revealed no abnormalities. Intraoral examination showed a mesio-occlusal cavity (approximately 9 × 5 mm) on tooth 16 with gutta-percha exposure (Fig. 1A), without swelling or sinus tract formation. The tooth exhibited moderate tenderness to percussion, while palpation was non-tender. Periodontal probing depths were within normal limits.

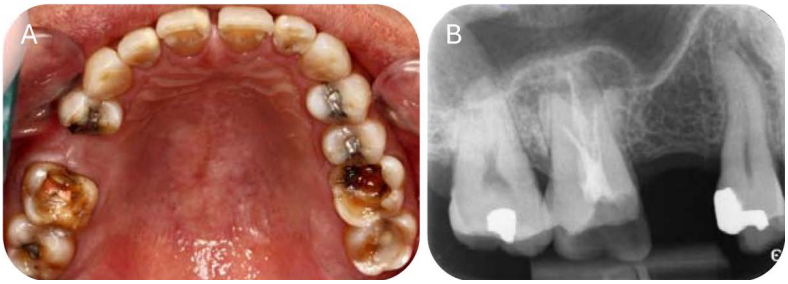

Figure 1 (A) Intraoral photograph of the maxillary arch, and (B) Periapical radiograph of teeth 14, 16, 17, and the edentulous area corresponding to tooth 15

A periapical radiograph taken with the paralleling technique (Fig. 1B) revealed a radiolucent lesion on the occluso-mesial surface of tooth 16, approximately 9 mm mesiodistally and 4 mm in depth. The mesial cavity margin was located 4 mm coronal to the crestal bone. An elongated pulp chamber containing radiopaque gutta-percha was noted. The tooth exhibited three roots with an unusually high furcation and an apically displaced pulpal floor, consistent with taurodontism, classified as mesotaurodont according to Shifman and Chanannel (1978). Three canals were present, each showing non-homogeneous and inadequate root canal filling. The mesiobuccal (MB) canal filling was off-center and short by about 3 mm, while the distobuccal (DB) and palatal (P) canals were short by 5 mm and 2 mm, respectively. The lamina dura was intact to the apical thirds of roots before becoming indistinct. A periapical radiolucency was observed around the MB and DB root apices, measuring approximately 5 × 6 mm and 5 × 4 mm, respectively. The root apices were superimposed on the maxillary sinus floor, which showed localized expansion above the MB and DB roots.

After emergency treatment, CBCT imaging was performed using a small field of view (4 × 4 cm) and a voxel size of 0.07 mm with a NewTom Giano HR system (QR s.r.l., Verona, Italy) to evaluate the three-dimensional configuration of the root canal system.

Axially, radiopaque material was observed in the pulp chamber at the coronal third (Fig. 2A). Three canal orifices were identified at the middle third, with a radiolucent line extending toward the palatal direction along the MB root (arrow, Fig. 2B). Radiolucent dots suggestive of MB1 and MB2 canals, along with a radiopaque dot possibly indicating additional MB canal, were noted at the middle–apical level (arrow, Fig. 2C). Buccal bone perforation was visible at the apical third (Fig. 2D).

Coronal planes further demonstrated the three roots, confirming radiolucent lesions around the mesiobuccal and distobuccal apices with buccal bone perforation. They also showed overlap of the root apices with the maxillary sinus floor, which exhibited expansion and a radiopaque halo (Fig. 2E). The lamina dura remained intact throughout the palatal root (Fig. 2F). According to the criteria of Shifman and Chanannel (1978), the taurodontic index classified the tooth as hypertaurodontism.

Sagittal planes revealed periapical radiolucencies around the mesiobuccal root (5.5 × 6.2 mm) and the distobuccal root (5.4 × 4.9 mm). The root apices were adjacent to the maxillary sinus floor, which exhibited expansion above both roots with a radiopaque halo appearance. Buccal bone perforation was observed (Fig. 2G, 2H). According to the CBCT findings, the tooth was classified as hypertaurodontism.

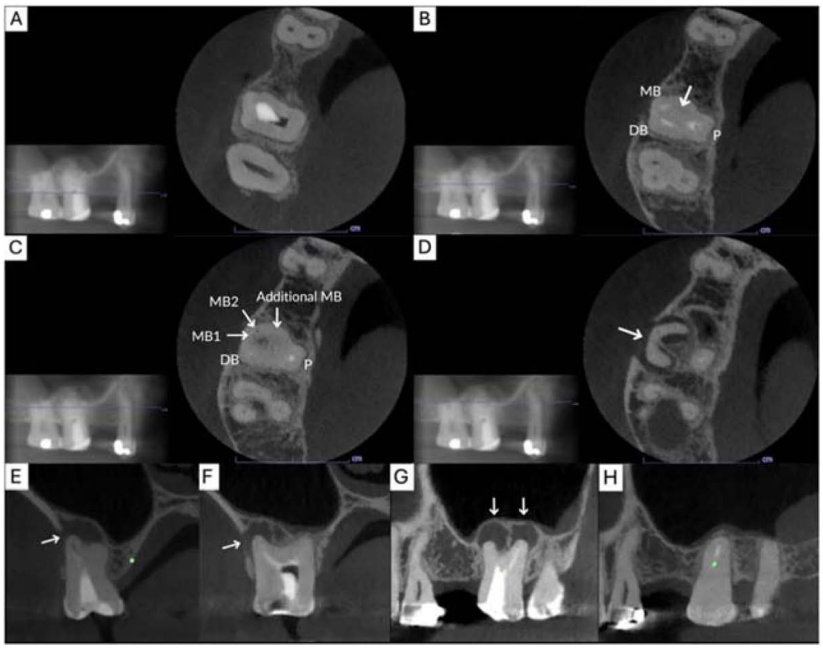

Figure 2 CBCT axial planes: (A) coronal third, (B) middle third, (C) junction between the middle and apical thirds, and (D) apical third; coronal planes: (E) mesiobuccal roots, and (F) distobuccal and palatal root; sagittal planes: (G) mesiobuccal and distobuccal root, and (H) palatal roots.

Diagnosis and treatment planning

Based on the clinical and radiographic findings, the pulpal diagnosis was previously treated, and the periapical diagnosis was symptomatic apical periodontitis (AAE, 2013).

The treatment plan aimed to eliminate infection and preserve the tooth. Based on the decision-making concept for previously treated teeth proposed by Friedman et al., the presence of clinical symptoms, a periapical lesion on the periapical radiograph, and accessible root canals supported the decision to perform non-surgical retreatment. Emergency management involved removal of the gutta-percha and initial canal debridement to relieve pain. The definitive treatment was non-surgical root canal retreatment (NS-ReTx), which allowed thorough cleaning, shaping, and disinfection of the root canal system. This approach was selected due to evidence of coronal leakage, incomplete obturation, and a suspected missed canal contributing to reinfection. Alternative treatment options included surgical root canal treatment, intentional replantation, or extraction. However, given the proximity of the roots to the maxillary sinus, the taurodont morphology with relatively short roots, and the patient's desire to retain the tooth, non-surgical retreatment was considered the most appropriate treatment approach. After consultation with a prosthodontist, a bridge restoration involving teeth 14 to 16 was planned following root canal retreatment to ensure functional rehabilitation and structural protection of the tooth.

The overall prognosis for this case was considered favorable. From an endodontic perspective, the cause of failure in the initial treatment was coronal leakage and inadequate cleaning of the root canal system. Retreatment could address these deficiencies through proper aseptic technique, adequate canal enlargement,

and effective irrigation to eliminate residual microorganisms; therefore, successful healing and long-term tooth preservation were expected. From a restorative standpoint, the tooth had sufficient remaining structure and an acceptable crown–root ratio and would receive a full-coverage restoration, supporting a favorable long-term functional outcome. In addition, periodontal examination revealed healthy supporting tissues.

Treatment procedure

The emergency visit involved managing previously treated tooth 16, where the dislodged restoration exposed poorly compacted gutta-percha. After administering local anesthesia and achieving rubber dam isolation, the remaining gutta-percha was removed from the coronal and chamber regions, allowing identification of three orifices (MB, DB, and P orifices). A #15 H-file was used to remove the gutta-percha from all three root canals. The periapical radiograph was taken after gutta-percha removal (Fig. 3). Working length estimation confirmed patency in the DB and P canals, while the MB canal could only be negotiated partially despite additional scouting attempts. Initial enlargement, irrigation with 2.5% NaOCl, and intracanal medicament placement with calcium hydroxide were completed,

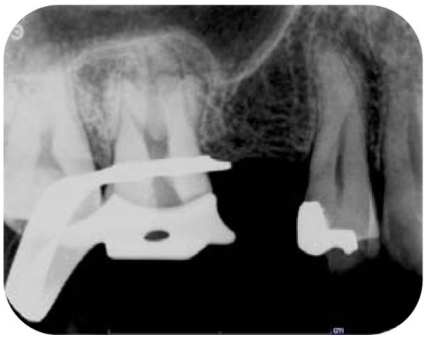

Figure 3 Periapical radiograph after complete removal of gutta-percha.

followed by temporary restoration and occlusal reduction. The visit revealed highly complex root canal anatomy consistent with taurodontism, prompting the need for further treatment under a dental operating microscope and CBCT evaluation to assess the canal morphology in three dimensions.

At the second visit, the patient reported no pain, and clinical examination revealed no tenderness to percussion or palpation. Rubber dam isolation was performed. Under the dental operating microscope, the temporary restoration was removed, and the canals were irrigated with 2.5% NaOCl. Canal scouting was continued using precurved C-file and K-file with EDTA cream. In the MB root, two canals (MB1 and MB2 canals) were identified but initial negotiation was difficult due to ledges and calcified pathways created during the previous treatment. Ultrasonic tips (ET18D and ET20D) were used to remove cervical dentin and improve straight-line access. A #10 C-file was precurved and gently worked around the obstruction using watch-winding and short push–pull motions until the original canal path was reached. Working lengths were established with an electronic apex locator and confirmed radiographically. Working length was established at 15 mm for MB1 canal and 16 mm for MB2 canal. Initial enlargement was performed with size #15-20 K-files. Due to narrow canals, low canal orifices, and short root length, rotary file insertion was initially difficult; therefore, careful hand instrumentation was required. Final shaping was completed using VDW Rotate rotary files with size 25/ .06 in MB1 and MB2 canals, size 30/ .04 in DB canal, and size 35/ .04 in P canal. Irrigation was performed using 2.5% NaOCl with a 30-gauge side-vented needle (TruNatomy) and passive ultrasonic irrigation (PUI). PUI was performed using an Irrisafe IRR20 irrigation tip (Acteon, Mérignac, France),

activated with an ultrasonic unit for 30 seconds per cycle (3 cycles). Due to canal curvature and deviation from the long axis, the ultrasonic tip was inserted as deep as possible without binding. The canals were dried, medicated with Ultracal® XS, temporized with Cavit™ and IRM, and occlusion was adjusted.

At the third visit, the patient remained asymptomatic, with no tenderness to percussion or palpation. Rubber dam isolation was performed. Under the operating microscope, additional canal scouting was done to locate a possible extra canal. A precurved C-file with size #10 was used along the mesial canal wall and directed palatally—corresponding to the additional MB location identified on CBCT (Fig. 2C). A catching point was detected at a mesio-palatal position consistent with CBCT findings, though the file could not initially advance. Cervical dentin was further removed using ultrasonic tips. With careful watch-winding motions and EDTA cream, the file gradually advanced to working length. Using the electronic apex locator, the additional MB working length was established at 15.5 mm, and radiograph was taken (Fig. 4). The canal was then enlarged with #15–20 K-files, followed by rotary shaping using VDW Rotate to size 25/ .06. The MB orifices were visible following rotary enlargement (Fig. 5). In addition, a pre-curved C-file was used to explore for potential additional canals along the developmental fusion line and at the junction between the canal walls and the pulpal floor; however, no further canals were identified. Irrigation was performed with 2.5% NaOCl using a 30-gauge side-vented needle and PUI. Medication was placed, and the tooth was temporized.

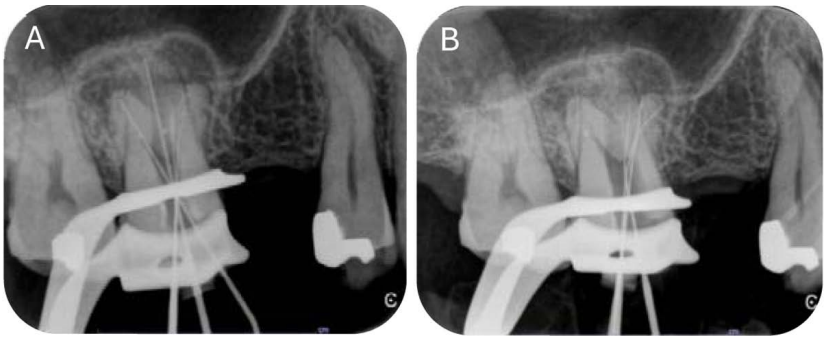

Figure 4 Working length determination radiographs: (A) MB1, MB2 (not patent), DB, and P canals; (B) MB1, MB2, and additional MB canal pathways after further negotiation.

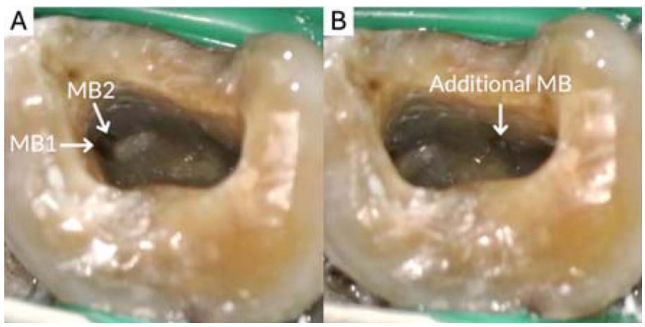

Figure 5 Orifices after rotary enlargement under the operating microscope: (A) MB1 and MB2 canals located within the same orifice; (B) additional MB canal positioned more toward the palatal aspect.

At the obturation visit, the patient was asymptomatic. Clinical examination revealed no tenderness to percussion or palpation, no swelling, and no sinus tract. Calcium hydroxide was removed, master cone selection was performed, followed by radiographic confirmation (Fig. 6A). Canals were irrigated with 2.5% NaOCl followed by 17% EDTA and a final rinse of NaOCl. XP-Endo Finisher #25 was used 1 mm short of the working length and activated. After drying with paper points, obturation was performed using gutta-percha and iRoot SP bioceramic sealer with hydraulic condensation (Fig. 6B). Due to the extremely short root lengths (approximately 4-5 mm), gutta-percha cones were cut at the canal orifice level to preserve space for a core buildup. The pulp chamber was cleaned, and the tooth was temporized.

Follow-up at two weeks revealed that the temporary restoration remained intact, and the patient was asymptomatic. A periapical radiograph was obtained (Fig. 7A). The patient was referred for definitive restoration. At 2-month follow-up after placement of the final restoration, the fixed dental bridge was intact, with no tenderness to percussion or palpation, no mobility, normal periodontal probing depths, and no swelling or sinus tract. The patient remained asymptomatic. The periapical radiograph demonstrated a reduction in the size of the periapical lesion (Fig. 7B).

At the 2-year recall, the patient remained asymptomatic. Intraoral examination revealed a well-adapted bridge with good margin. The tooth was non-tender to percussion and palpation, exhibited no mobility, and showed normal periodontal probing depths. Radiographically, a continuous lamina dura and normal periodontal ligament space were observed along the entire root length, with a normal alveolar bone crest and trabecular pattern (Fig. 7C), indicating complete healing. The previously noted halo-like periapical radiolucency had completely healed (Fig. 8). CBCT imaging demonstrated complete resolution of the previously observed maxillary sinus mucosal thickening. The sinus floor cortical boundary appeared continuous and well-defined, with no residual inflammatory changes. These findings coincided with complete osseous healing of the periapical lesion.

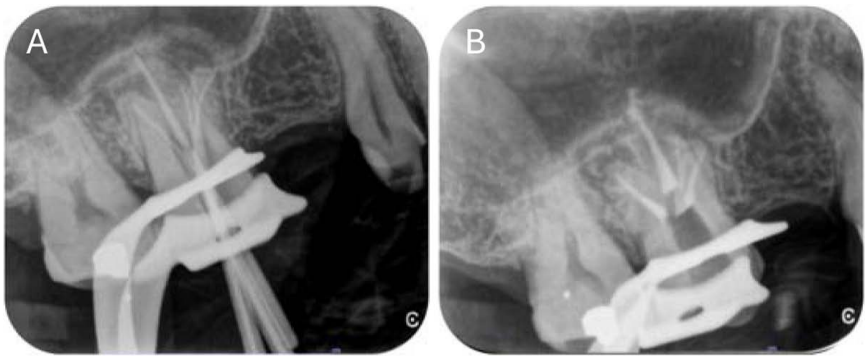

Figure 6 (A) Periapical radiograph showing master cone selection; (B) Final obturation radiograph demonstrating completed root canal filling.

Figure 7 Follow-up radiographs demonstrating progressive healing: (A) 2-week follow-up; (B) 2-month follow-up; (C) 2-year recall.

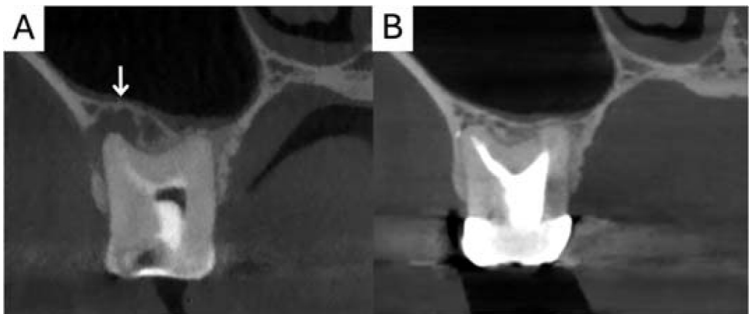

Figure 8 CBCT comparison before and after treatment: (A) Initial CBCT showing a halo-like periapical radiolucency (white arrow); (B) 2-year recall demonstrating complete healing of both the periapical lesion and associated sinus changes.

Discussion

Taurodontism presents significant endodontic challenges due to its atypical root morphology, including an enlarged pulp chamber, apically positioned pulpal floor, and shortened roots (6). These anatomical variations often obscure canal orifices, complicate canal negotiation, and increase the risk of missed anatomy or procedural errors during both primary treatment and retreatment. Previous studies have reported the presence of additional canals in taurodont teeth (9). In the present case, the taurodont configuration contributed to underfilled canals and persistent periapical pathology following the initial root canal therapy. In addition, coronal leakage, inadequate canal preparation and obturation may have further contributed to the persistence of apical periodontitis. This case highlights the importance of careful exploration of the pulp chamber and thorough cleaning, shaping, and obturation to manage anatomical complexities and improve treatment outcomes.

CBCT played a critical role in diagnosis and treatment planning (10, 11). In addition to confirming the taurodont morphology, CBCT enabled the identification of an additional mesiobuccal canal, which could not be visualized clinically. The use of a dental operating microscope further facilitated the detection, negotiation, and instrumentation of all canals, supporting the principle that magnification and illumination significantly enhance the identification of complex canal systems (16). Based on CBCT evaluation, the taurodontic index classified the tooth as hypertaurodontism, which differed

from the assessment obtained using periapical radiography, where the tooth was classified as mesotaurodontism. According to Jabali A.H. et al., CBCT is recommended for the evaluation of taurodontism because of its higher diagnostic accuracy (17). In addition, CBCT allows more precise assessment of the depth and direction required for canal orifice location.

Durr et al. noted that taurodont morphology can hinder the identification of canal orifices, thereby complicating instrumentation and obturation (4). In the present case, the long axis of the roots did not align with that of the crown, further limiting straight-line access and reducing instrument control. As a result, mechanical instrumentation could not be initiated directly with rotary instruments. Canal negotiation and initial enlargement were performed using manual hand files, which were directed slightly opposite to the canal trajectory to facilitate file advancement and establish an initial glide path before introducing rotary instrumentation. In teeth with shortened roots, careful tactile control and frequent verification of the working length are particularly important to prevent apical over-preparation. Additionally, the canal orifices were partially calcified, necessitating the removal of the dentin shelf with ultrasonic tips and the creation of adequate coronal flaring using a crown-down approach with hand files (18). Careful examination of the grooves between orifices under magnification has been recommended for locating additional canals (3, 19). A pre-curved C-file was used to explore the root developmental fusion line and the pulpal floor junction, but no extra canals were detected in this case.

Due to the complex anatomy, complete debridement and obturation of taurodont teeth can be particularly challenging (6). In this case, the patient also presented with maxillary sinusitis of endodontic origin, radiographically evidenced as periapical osteoperiostitis. MSEO results from the extension of periapical infection into the Schneiderian membrane, and its diagnosis relies on correlating clinical symptoms with both periapical and sinus radiographic findings (12, 20). Differential diagnosis includes allergic sinusitis, odontogenic sinusitis of non-endodontic origin, mucous retention cysts, antral polyps, and postoperative sinus changes, highlighting the need for careful interpretation (12). CBCT is especially valuable both in the initial diagnosis and in follow-up of MSEO, as periapical radiographs may underestimate residual sinus membrane alterations (14, 15, 21). Because MSEO originates from odontogenic infection associated with apical periodontitis, elimination of the intraradicular infection through adequate root canal disinfection is essential for resolution of both the periapical and sinus pathology. In this case, non-surgical retreatment successfully eliminated the infectious source, and CBCT follow-up confirmed complete resolution of both periapical and sinus changes without the need for surgical or adjunctive medical interventions (Fig. 8B).

In addition, supplemental irrigation techniques may enhance root canal disinfection in teeth with complex anatomy. In taurodont teeth, the enlarged pulp chamber and irregular canal configuration may reduce the effectiveness of conventional syringe irrigation. Therefore, adjunctive methods such as PUI or the XP-endo Finisher have been recommended to improve irrigant penetration and biofilm disruption, particularly in areas that are difficult to instrument (6).

The use of hydraulic condensation with hydraulic calcium silicate-based cements was appropriate given the limited root length and the need for a fluid-tight seal in complex anatomy. Bioceramic sealers offer several advantages, including excellent biocompatibility, bioactivity, and slight setting expansion, which enhances adaptation to irregular canal walls (22-24). However, their high flowability and hydraulic properties may increase the risk of extrusion. In this case, minor bioceramic extrusion was observed, but previous studies suggest that such extrusion does not negatively affect healing (25, 26). Moreover, bioceramic sealers have been reported to be less toxic than conventional sealers, such as AH Plus (27, 28), and to exhibit less apical microleakage from microorganisms (29, 30). Consistent with this evidence, the present case showed complete healing at the two-year follow-up.

According to previous studies, post placement is generally not recommended in the restoration of taurodont teeth (6, 19). The elongated pulp chamber itself provides substantial internal retention for the core when adequate coronal dentin remains. The decision to terminate gutta-percha at the orifice level preserved structural dentin and ensured sufficient space for core retention—an important consideration in taurodont teeth with large pulp chambers.

Overall, this case demonstrates that careful anatomical assessment, use of CBCT, magnification, activating irrigation, and a methodical retreatment approach can lead to successful outcomes in taurodont molars with MSEO. The long-term follow-up confirmed complete periapical and sinus healing, reinforcing non-surgical retreatment as the primary and effective modality for managing both complex internal anatomy and sinus manifestations of endodontic infection.

Conclusion

Non-surgical retreatment of taurodont teeth with complex canal anatomy and MSEO can achieve favorable outcomes when supported by CBCT imaging, magnification, and advanced irrigation techniques. Awareness of potential anatomical variations is essential to facilitate comprehensive cleaning, shaping, and obturation.

References

1. Keith A. Problems relating to the teeth of the earlier forms of prehistoric man. **Proc R Soc Med**. 1913;6(Odontol Sect):103-24.
2. Terezhalmy GT, Riley CK, Moore WS. Clinical images in oral medicine and maxillofacial radiology. Taurodontism. **Quintessence Int**. 2001;32(3):254-5.
3. Yeh SC, Hsu TY. Endodontic treatment in taurodontism with Klinefelter's syndrome: A case report. **Oral Surg Oral Med Oral Pathol Oral Radiol Endod**. 1999;88(5):612-5.
4. Durr DP, Campos CA, Ayers CS. Clinical significance of taurodontism. **J Am Dent Assoc**. 1980;100(3):378-81.
5. Sert S, Bayrl G. Taurodontism in six molars: a case report. **J Endod**. 2004;30(8):601-2.
6. Jafarzadeh H, Azarpazhooh A, Mayhall JT. Taurodontism: a review of the condition and endodontic treatment challenges. **Int Endod J**. 2008;41(5):375-88.
7. Hamner JE 3rd, Witkop CJ Jr, Metro PS. Taurodontism; report of a case. **Oral Surg Oral Med Oral Pathol**. 1964;18:409-18.

8. Shifman A, Chanannel I. Prevalence of taurodontism found in radiographic dental examination of 1,200 young adult Israeli patients. **Community Dent Oral Epidemiol**. 1978;6(4):200-3.
9. Hayashi Y. Endodontic treatment in taurodontism. **J Endod**. 1994;20(7):357-8.
10. Kiarudi AH, Eghbal MJ, Safi Y, Aghdasi MM, Fazlyab M. The applications of cone-beam computed tomography in endodontics: a review of literature. **Iran Endod J**. 2015;10(1): 16-25.
11. Scarfe WC, Levin MD, Gane D, Farman AG. Use of cone beam computed tomography in endodontics. **Int J Dent**. 2009;2009:634567.
12. Maxillary sinusitis of endodontic origin: AAE position statement; american association of endodontists [Internet]. 2018 [cited 20 September 2025]. Available from: https://www.aae.org/specialty/wp-content/uploads/sites/2/2018/04/AAE_PositionStatement_MaxillarySinusitis.pdf
13. Worth HM, Stoneman DW. Radiographic interpretation of antral mucosal changes due to localized dental infection. **J Can Dent Assoc (Tor)**. 1972;38(3):111-6.
14. Lofthag-Hansen S, Huumonen S, Gröndahl K, Gröndahl HG. Limited cone-beam CT and intraoral radiography for the diagnosis of periapical pathology. **Oral Surg Oral Med Oral Pathol Oral Radiol Endod**. 2007;103(1): 114-9.
15. Low KM, Dula K, Bürgin W, von Arx T. Comparison of periapical radiography and limited cone-beam tomography in posterior maxillary teeth referred for apical surgery. **J Endod**. 2008; 34(5):557-62.
16. Karapinar-Kazandag M, Basrani BR, Friedman S. The operating microscope enhances detection and negotiation of accessory mesial canals in mandibular molars. **J Endod**. 2010;36(8):1289-94.
17. Jabali AH, Chourasia HR, Wasli AS, Alkhayrat AM, Mahnashi HM, Kamly MJ, et al. Taurodontism in maxillary and mandibular molars using cone beam computed tomography in a dental center in Saudi Arabia. **Ann Saudi Med**. 2021;41(4):232-7.
18. McCabe PS, Dummer PM. Pulp canal obliteration: an endodontic diagnosis and treatment challenge. **Int Endod J**. 2012;45(2):177-97.
19. Tsesis I, Shifman A, Kaufman AY. Taurodontism: an endodontic challenge. Report of a case. **J Endod**. 2003;29(5):353-5.
20. Gomes A, Bueno C, De Martin A, Stringheta C, Fontana C, Pedro D, et al. Association of maxillary sinus reactions and periapical pathology in the maxillary posterior teeth: evaluation using cone beam computed tomography. **Braz Dent J**. 2024;35.
21. Matsumoto Y, Ikeda T, Yokoi H, Kohno N. Association between odontogenic infections and unilateral sinus opacification. **Auris Nasus Larynx**. 2015;42(4):288-93.
22. Al-Haddad A, Che Ab Aziz ZA. Bioceramic-Based Root Canal Sealers: A Review. **Int J Biomater**. 2016;2016:9753210.
23. Pawar SS, Pujar MA, Makandar SD. Evaluation of the apical sealing ability of bioceramic sealer, AH plus & epiphany: An in vitro study. **J Conserv Dent**. 2014;17(6):579-82.
24. Candeiro GT, Correia FC, Duarte MA, Ribeiro-Siqueira DC, Gavini G. Evaluation of radiopacity, pH, release of calcium ions, and flow of a bioceramic root canal sealer. **J Endod**. 2012;38(6):842-5.

25. Chybowski EA, Glickman GN, Patel Y, Fleury A, Solomon E, He J. Clinical outcome of non-surgical root canal treatment using a single-cone technique with endosequence bioceramic sealer: a retrospective analysis. **J Endod**. 2018;44(6):941-5.
26. Li J, Chen L, Zeng C, Liu Y, Gong Q, Jiang H. Clinical outcome of bioceramic sealer iRoot SP extrusion in root canal treatment: a retrospective analysis. **Head Face Med**. 2022;18(1):28.
27. Zhang W, Li Z, Peng B. Ex vivo cytotoxicity of a new calcium silicate-based canal filling material. **Int Endod J**. 2010; 43(9): 769-74.
28. Chang SW, Lee SY, Kang SK, Kum KY, Kim EC. In vitro biocompatibility, inflammatory response, and osteogenic potential of 4 root canal sealers: Sealapex, Sankin apatite root sealer, MTA Fillapex, and iRoot SP root canal sealer. **J Endod**. 2014;40(10):1642-8.
29. Bidar M, Sadeghalhoseini N, Forghani M, Attaran N. Effect of the smear layer on apical seals produced by two calcium silicate-based endodontic sealers. **J Oral Sci**. 2014;56(3): 215-9.
30. Gandhi B, Halebathi-Gowdra R. Comparative evaluation of the apical sealing ability of a ceramic based sealer and MTA as root-end filling materials - An in-vitro study. **J Clin Exp Dent**. 2017;9(7):e901-e5.