Volume 5(1) January - June 2026

TEJ

Thai Endodontic Journal (ENDOSARN)
วารสารเอ็นโดดอนติกส์ไทย (เอ็นโดสาร)

The official journal of the Thai Endodontic Association

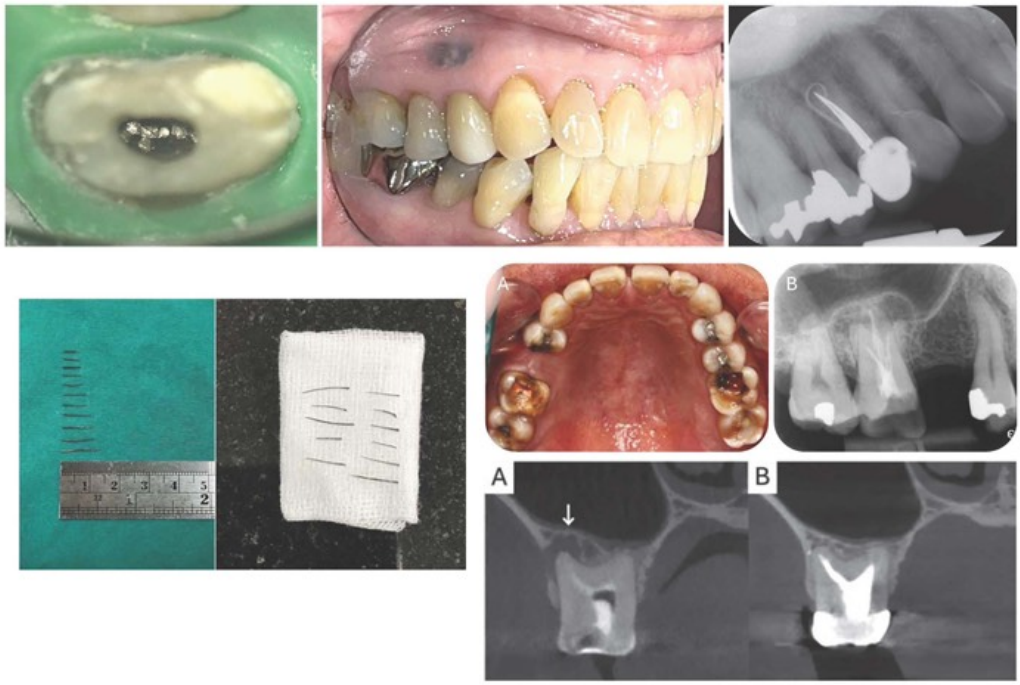

Interesting articles

- ***Non-surgical Retreatment of a Taurodont Molar with Maxillary Sinusitis of Endodontic Origin: A Case Report***
- ***Non-surgical root canal retreatment: a case report of eleven silver cones removal in maxillary first premolar***
- ***Minimal invasive endodontics: A comprehensive review on access preparation and mechanical instrumentation strategies - Part I: access cavity design***

Text and Journal Publication Co., LTD.

ISSN 1685-3709

Non-surgical root canal retreatment: a case report of eleven silver cones removal in maxillary first premolar

Sirawut Hiran-us

Department of Operative Dentistry, Faculty of Dentistry, Chulalongkorn University

Abstract

Modern endodontic therapy dismissed the use of silver cones as root canal filling due to their corrosion susceptibility, which ultimately leads to endodontic failure. When non-surgical retreatment is required, removal of silver cones can be challenging and potentially cause separation into fragments, which may complicate retreatment procedures. This case report discusses a 68-year-old female patient presenting with a sinus tract at the root apex of the maxillary right first premolar, accompanied by local argyrosis in the adjacent soft tissue. Radiographic analysis suggested the presence of laterally condensed silver cones within the root canals, with radiolucency evident at the apical region. Eleven silver cones were successfully retrieved from both canals without fragmentation, using Hedström files and a braiding technique. The unusual finding of eleven cones in a single premolar tooth, along with local argyrosis, highlights the uniqueness of this case. Following root canal disinfection, the sinus tract resolved, and one-year follow-up radiographs showed continued periapical healing. This case report suggests the effectiveness of utilizing Hedström files in conjunction with a braiding technique as a viable method for retrieving silver cones while minimizing the risk of separation.

Keywords: root canal retreatment, non-surgical retreatment, silver cone removal, braiding technique, local argyrosis

Correspondence: Sirawut Hiran-us

Department of Operative Dentistry, Faculty of Dentistry, Chulalongkorn University

Contact number: 081-205-5775

E-mail: Sirawut.h@chula.ac.th

Received: 16 December 2025 **Revised:** 25 April 2026 **Accepted:** 5 May 2026

Introduction

The use of silver cones as root canal obturation material was introduced during the mid-20th century, designed to align with the size and taper of 0.02 hand files. These cones facilitate easy insertion into the root canal system and support adequate length control during root canal obturation. However, their lack of plasticity hinders their ability to conform to the irregularities of the canal anatomy, resulting in inadequate filling of the root canal space. This deficiency can lead to leakage and the spontaneous corrosion of silver cones in the presence of biological fluids, such as serum or blood, owing to unstable electrochemical behavior. The byproducts of such corrosion have been documented to cause irreversible staining of the surrounding mucosa and the affected tooth, a phenomenon referred to as local argyrosis (1-3). Consequently, modern endodontic therapy as endorsed by the American Association of Endodontists (AAE) Position Statement, does not recommend the use of silver cones due to their associated disadvantages (4).

In instances where a tooth has already been obturated with silver cones, prophylactic retreatment is not advised unless there is clear periradicular pathosis, or if the presence of silver cones obstructs the fabrication of a final restoration or complicates post and core build ups or apical surgeries (4). Non-surgical endodontic retreatment involving the retrieval of silver cones presents significant challenges due to the material's soft nature, which increases the risk of separation during mechanical manipulation and complicates the retreatment procedure. Typically, teeth obturated with silver cones contain a single cone per canal. Conversely, this report describes and unusual case involving the presence of multiple cones within a maxillary first premolar, a scenario that has not been extensively documented. The removal of several silver cones from the root canal proved to be particularly challenging. The objective of this article is to emphasize the treatment rationale and decision-making process in this case, while detailing the successful procedures and methods employed for the retrieval of multiple silver cones from a maxillary first premolar tooth.

Case Report

A 68-year-old Thai female with a history of hypertension, hyperlipidemia, and glaucoma was referred to the postgraduate endodontics department for retreatment of her maxillary right first premolar (tooth 14). During a routine dental examination, a sinus tract opening was identified at the buccal gingiva of the affected tooth. The patient was unaware of this condition and reported no previous symptoms. The patient's dental history revealed that tooth 14 had undergone root canal treatment and was restored with a porcelain-fused-to-metal crown at another facility approximately 40 years ago.

Extraoral examination showed no facial swelling or asymmetry, and mandibular opening was adequate. Intraoral examination revealed an open margin porcelain-fused-to-metal crown on the buccal aspect, without signs of traumatic occlusion in either centric or eccentric occlusal positions. The sinus tract opening was visibly located at the buccal gingiva, aligned with the root apex of tooth 14, and a localized area of black pigmentation was noted in the surrounding gingiva, suggestive of local argyrosis (Figure 1). Notably, the tooth exhibited negative responses to percussion and palpation, with no mobility or soft tissue swelling present. Periodontal probing depths ranged from 2-3 mm around the tooth, and pulpal sensibility tests were not conducted as the tooth was endodontically treated.

Figure 1 Sinus tract opening at the buccal gingiva, aligned with the root apex of tooth 14, and a localized area of black pigmentation was noted in the surrounding gingiva, suggestive of local argyrosis.

Pre-operative periapical radiographs revealed a metallic radiopacity covering the crown, consistent with the intraoral findings of the porcelain-fused-to-metal crown. Within the root canals, a streak of homogeneous metallic radiopacity were observed, extending from the coronal aspect to the apex. This suggested the presence of silver cones utilized as root canal filling materials. A horizontally angulated radiograph further illustrated multiple streaks of metallic radiopacity, further supporting the suspicion of multiple silver cones, likely placed using a lateral condensation technique. Gutta-percha tracing confirmed that the tract extended to the apex of tooth 14, with an associated periapical radiolucency at apical third of the root, measuring approximately 1x3 mm in size. The alveolar bone crest level was within normal limits, indicating that the surrounding bone structure was preserved (Figure 2 and Figure 3).

Figure 2 Pre-operative radiograph. A metallic radiopacity around the crown, indicating a porcelain-fused-to-metal crown. A consistent streak of metallic radiopacity is also observed within the root canals, extending from the crown to the apex, suggesting the presence of silver cones used for root canal filling. The alveolar bone crest level was within normal limits.

Figure 3 Pre-operative radiograph with horizontally angulated, and gutta-percha tracing. The presence of multiple streaks of metallic radiopacity reinforces the suspicion of several silver cones, likely obturated through a lateral condensation technique. Gutta-percha tracing indicated that the tip terminated at the apex of tooth 14, accompanied by a periapical radiolucency at the apex measuring approximately 1x3 mm in size.

Treatment planning and rationale

Based on clinical and radiographic evaluations, the endodontic diagnosis for tooth 14 was previously treated with chronic apical abscess. As the tooth was previously obturated using multiple silver cones and exhibits an associated sinus tract.

The proposed ideal treatment plan includes the removal of the existing crown, fabrication of a temporary crown, and non-surgical endodontic retreatment, which entails the removal of the silver cones. This will be followed by re-obturation with gutta-percha and placement of a prefabricated post, composite core, and a zirconia crown for final restoration. Coronal leakage of the root canal system was suspected due to an open margin on the porcelain-fused-to-metal crown, which supported the decision to remove the crown. The previous obturation with silver cones may also have contributed to apical leakage and corrosion. Non-surgical retreatment is preferred to re-disinfect the root canal system, allowing for effective re-obturation. Although there may be challenges in removing the silver cones, access to the root canal can still be achieved through a coronal approach. A fiber post will be placed to support the core build-up and facilitate more favorable distribution of occlusal forces. Given the esthetic considerations for tooth 14, zirconia is selected as the final restoration material due to its strength, durability, and superior esthetic properties. The patient has chosen to proceed with this treatment plan, which will be discussed in further detail later.

Two alternative treatment options were discussed. The first option involved an apicoectomy, followed by root-end preparation and retrograde filling with mineral trioxide aggregate (MTA). Tooth 14 is a suitable candidate for endodontic microsurgery due to its accessible location, not being adjacent to vital anatomical structures. The second option presented was extraction followed by dental prosthetic replacement, while not recommended, this option was discussed

should the patient elect not to retain the tooth. Potential replacements could include a dental implant or a removable partial denture.

The given prognosis for tooth 14 is questionable, primarily due to anticipated challenges associated with the removal of silver cones. These cones appear to be tightly packed, likely as a result of lateral condensation during the previous obturation. Radiographic evaluation indicates that the silver cones extend to or slightly below the canal orifices, which may limit the efficiency of some retrieval instruments. Furthermore, considering that the treatment was performed approximately 40 years ago, it is possible that an older-generation zinc-phosphate cement was used. These materials may be more difficult to remove compared with modern resin-based sealers. Failure to remove the previous root canal obturation and regain patency to the apical terminus may compromise canal disinfection and adversely affect the endodontic treatment outcome.

Treatment procedures

Treatment commenced with the removal of the porcelain-fused-to-metal crown, which exposed an intact composite core devoid of secondary caries and exhibited no significant marginal leakage. Following rubber dam isolation, an access opening was established by removing the composite core within the access outline. The core was meticulously removed using an Acteon ET20D ultrasonic tip until the shank of the silver cones became visible.

Under the dental operating microscope, seven silver cones were initially identified within the canal (Figure 4), with little evidence of the surrounding root canal cement discernible. A bypassing technique was employed utilizing small K-files (ISO sizes 10 and 15), which were maneuvered adjacent to the silver cones to create lateral or circumferential space around each cone. This procedural step is vital for accommodating multiple file placements during subsequent removal attempts.

Figure 4 Following rubber dam isolation and the removal of the composite core, seven silver cones were observed within the canal under a dental operating microscope, accompanied by minimal evidence of surrounding root canal cement. This finding supported the hypothesis that the tooth had been previously obturated using laterally condensed silver cones.

Initial bypassing was achieved to a depth of approximately 12-13 mm from the occlusal surface, with the provisional length of the root canal estimated at 15-16 mm The retrieval of five silver cones was conducted sequentially. Some cones could be retrieved using only a single Hedström file, while others necessitated the application of a braiding technique. In this technique, multiple Hedström files were simultaneously inserted into the canal, arranged circumferentially around the bypassed. The files were then twisted to create a tight interlocking grip around the cone prior to removal.

After the removal of five silver cones, a canal septum separating the two canals within the tooth became visible, confirming that the palatal canal had been successfully cleared. A distally angulated periapical radiograph was subsequently obtained to confirm the presence of any remaining silver cones within the buccal canal (Figure 5).

The remaining silver cones within the buccal canal were subsequently retrieved utilizing either a single engagement of a Hedström file or in conjunction with a braiding technique. The silver cone located furthest buccally was the first to be mobilized, suggesting it may have been the last cone placed during the prior obturation. This cone was not obstructed by any other cones. Following the removal of this cone, six additional silver cones were successfully retrieved from the buccal canal. In total, eleven silver cones were removed from the premolar tooth without any fragmentation or separation, as shown in Figure 6.

A periapical radiograph was obtained to confirm the complete removal of all cones (Figure 7). The working lengths of both canals were then assessed (Figure 8). Mechanical instrumentation of the canals was performed using rotary instruments, targeting a master apical size of 40 for both canals. Throughout these procedures, a 2.5% sodium hypochlorite solution was utilized, supplemented by passive ultrasonic irrigation. For intracanal medication, an injectable premixed calcium hydroxide paste was employed.

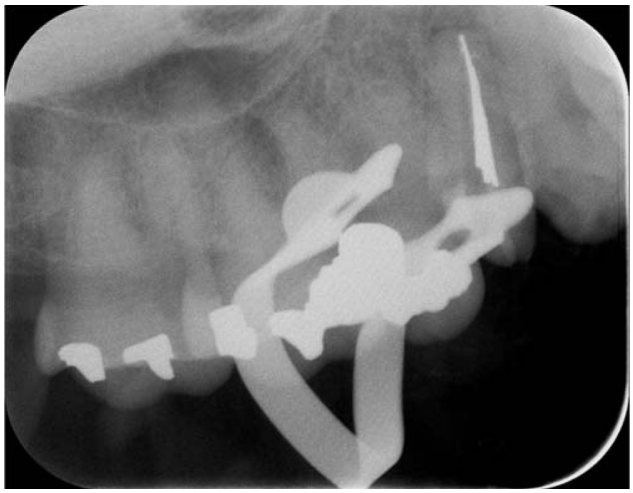

Figure 5 Following the removal of six silver cones from the palatal canal, a periapical radiograph angled distally was obtained to verify the presence of additional silver cones still situated within the buccal canal that had not yet been retrieved.



Figure 6 By carefully bypassing around the cone to ensure adequate surrounding space, followed by the utilization of Hedström files alongside a braiding technique, a total of eleven silver cones were successfully retrieved from both canals without any fragmentation or separation.

Figure 7 A periapical radiograph taken to ensure complete removal of all silver cones without any fragmentation or separation.

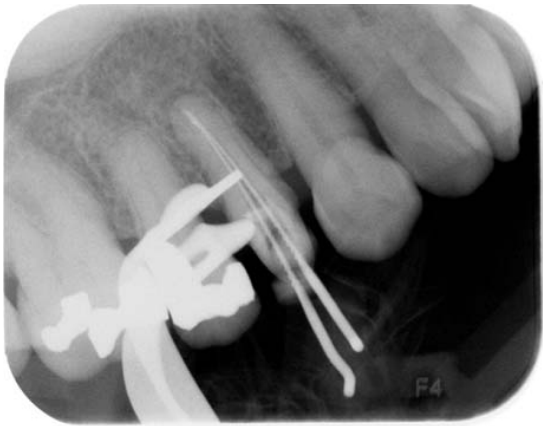

Figure 8 A periapical radiograph illustrates the determination of working length of tooth 14. Two canal orifices were identified, separated by a septum; however, the apical portions of both canals converged, as indicated by the configuration of the files.

The pulp chamber was temporarily sealed with Cavit, and a provisional crown was secured with a self-curing, zinc oxide non eugenol-based temporary cement between appointments. Despite multiple sessions of mechanical debridement, a traceable sinus tract opening persisted. The master apical file size was subsequently increased to 45 for both canals. Additionally, 2% chlorhexidine was utilized for additional irrigation, complemented by the application of passive ultrasonic irrigation.

Consequently, the intracanal medicament was replaced with a modified triple antibiotic paste, which contains a mixture of doxycycline, ciprofloxacin, and metronidazole. This paste was positioned below the cementoenamel junction (CEJ) to minimize the risk of tooth discoloration. Since the tooth had already undergone cuspal coverage restoration, aesthetic concerns regarding discoloration were deemed minimal. The triple antibiotics paste served as an adjunct intracanal medication to provide additional antimicrobial activity when the conventional disinfection protocol proved ineffective.

The patient was recalled two weeks later, at which point the sinus tract opening on the buccal aspect had resolved, and the patient reported no symptoms. Following the selection of the main gutta-percha cones, the canals were irrigated with a 17% EDTA solution, followed by 2.5% sodium hypochlorite. The canals were then dried using paper points, and root canal obturation was completed with a resin-based root canal sealer employing the lateral condensation technique (Figure 9). In subsequent appointments, prefabricated posts were cemented in both canals using Multicore Flow, and a new zirconia crown was delivered to the patient as the final restoration.

One-year post-treatment, the patient returned for a follow-up evaluation, reporting no symptoms since the completion of root canal retreatment. Intraoral examination revealed a zirconia crown that maintained proper integrity, exhibiting adequate proximal contact and shade matching with adjacent natural teeth. No occlusal interference, fremitus, or tooth mobility was detected. The tooth was negative to percussion, and the surrounding soft tissue appeared normal, showing no tenderness on palpation, swelling, or signs of a recurrent sinus tract.

Figure 9 A periapical radiograph taken after complete root canal obturation.

Notably, an area of local argyrosis was still observed at the previous sinus tract opening site. This area was inconspicuous during smiling and was not deemed aesthetically concerning by the patient. Periodontal probing depths were recorded within normal limits, ranging from 2-3 mm around the tooth.

Radiographic assessment indicated an area of widened periodontal ligament space at the apical segment of tooth 14. Additionally, there was an increased visibility of the lamina dura compared to pre-operative radiographs (Figure 10). These observations suggest ongoing, yet incomplete periapical healing of the tooth. The patient has been scheduled for a subsequent evaluation in one year, marking the two-year follow-up post-treatment completion.

Discussions

In contemporary endodontic practice, clinicians frequently encounter cases of endodontic failure associated with root canals previously obturated using silver cone. In such instances, endodontic microsurgery may be considered as an option, particularly due to advancements in surgical techniques and instrument development over the recent years. However, if the integrity of the coronal restoration is compromised, potentially leading to leakage within the root canal system, a non-surgical retreatment approach may be preferable if the canals can be accessed by coronal approach. This strategy allows for thorough disinfection of the root canal system and effective re-obturation, ultimately targeting intraradicular infection, which is recognized as the primary cause of endodontic failure (5-8).

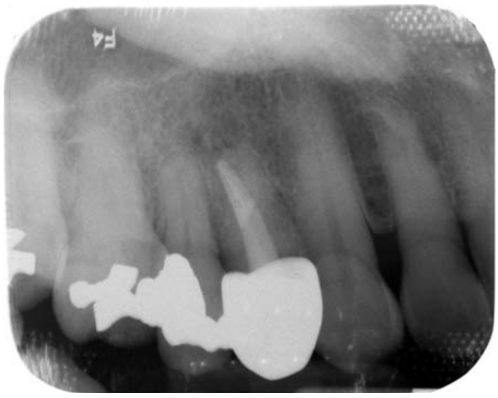

Figure 10 The one-year post-operative follow-up radiograph reveals evidence of ongoing, though incomplete periapical healing. Notably, the apical portion of tooth 14 demonstrates a persistent area of widened periodontal ligament space, although this area has decreased in size. Furthermore, there is an observable enhancement in the visibility of the lamina dura at the apical segment of the root when compared to the pre-operative radiograph.

Previous studies have described various techniques for the removal of silver cones. In some cases, a combination of methods may improve the efficiency and success of retrieval. It is important to recognize that cases requiring silver cone removal often involve long-standing intraradicular leakage, which can compromise the seal and retention of the obturated cone. Typically, the apical portion of the canal is mechanically prepared to match the parallel taper of the silver cone, whereas the coronal and middle thirds are often flared, thereby facilitating access during removal procedures. The presence of coronal flaring and leakage may make retrieval appear relatively straightforward. However, silver cones are inherently soft and fragile, increasing the risk of separation—particularly when the apical segment is tightly fitted to the prepared canal.

Piezoelectric ultrasonic systems, such as the Satelec P5 or ProUltra ENDO tips, have been suggested as effective tools for removing core build-ups, including silver cones (9). However, caution is warranted to avoid applying direct ultrasonic vibrations to the silver cone. Given the malleable nature of silver, excessive vibration may cause the cone to separate into smaller fragments, complicating removal. Instead, ultrasonic energy should be applied circumferentially around the cone using adjunctive instruments, such as an endodontic spreader, to disrupt the surrounding cement or create a trough in the coronal portion of the canal. This approach facilitates loosening of the cone and enhances the likelihood of successful removal (10).

Specially designed pliers, such as Stieglitz forceps, hemostats, needle holders, or Perry Pliers, can be employed to grasp the exposed portion of the loosened cone (9, 11, 12). However, the restricted access size may limit the ability to grasp and manipulate instruments effectively. A combination of pliers may enhance grip stability on the cone and serve as an additional handle to apply extricating force (13). Utilizing pliers in conjunction with indirect ultrasonic vibrations, where the ultrasonic tip is placed in contact with the pliers, can improve removal efficiency by transmitting energy directly onto the instrument (10). In cases where coronal access is limited, particularly in premolar teeth, mechanical extraction using forceps or other hand instruments may prove impractical.

An automated device, such as the Canal Finder System, has been reported to facilitate effective in silver cone removal. By utilizes ISO 08 or 10 hand files to penetrate the surrounding sealer and bypass the cone, the instrument activation will subsequently allow for successful retrieval. However, its effectiveness is primarily observed in canals that can be bypassed by several millimeters. One advantage of this instrument is its ability to navigate narrow and curved canals with precision (14, 15). Alternatively, a specially designed Masserann kit, which is commonly used to extract posts or broken instruments, can serve a similar removal purpose. However, this kit necessitates a significant amount of coronal tooth structure prior to engaging the instrument tip, which may render it less effective in curved canals or for cones situated in the apical segments of the root canal (16).

In the current case , the restricted access size of a maxillary premolar tooth, coupled with the positioning of the silver cones, renders direct manipulation with instruments impractical.

Consequently, a bypassing technique was implemented alongside Hedström file engagement and a braiding technique. This method exclusively utilizes hand files, thereby obviating the need for additional instrument. This approach has also demonstrated success in earlier case report (17), and is effective when executed with care to minimize the risk of silver cone fragmentation. It is also advantageous in scenarios characterized by limited access or when direct engagement with instruments is unfeasible. When engaging the silver cone with a Hedström file, it is essential to ensure that the depth of instrument insertion matches the previously established bypassing depth. This depth should be approximately at the level of the apical segment of the cones. Failing to insert the Hedström file to this adequate depth may result in engaging the middle portion of the silver cone, increasing the risk of fracturing or separating the cone during retrieval. Proper insertion, up to the bypassed length, enhances the likelihood of successful retrieval without fragmentation. The key factor is to ensure adequate illumination and magnification under the dental operating microscope throughout the procedure.

While numerous case reports exist regarding silver cone removal, the present case is particularly noteworthy due to the presence multiple silver cones within a maxillary first premolar. The removal of several silver cones poses considerable challenges compared to cases with a single obturation. Despite the effectiveness of the techniques employed in this case, it is proposed that these techniques may offer a viable and beneficial strategy for a single-case scenario. It is also acknowledged that alternative techniques could be more suitable for different clinical situations, underscoring the importance of tailoring approaches to specific circumstances. Clinicians must exercise careful judgment in selecting appropriate techniques and in the manipulation of instruments when addressing such complex cases. Limitations of this report include the singular nature of the case and a limited follow-up duration.

Conclusion

This case report indicates that the utilization of Hedström files in conjunction with a braiding technique can be an effective method for removal of obturated silver cones. The findings highlight that careful bypassing and controlled engagement with the cones can minimize the risk of fragmentation and related procedural complications. This case exemplifies that conservative retreatment can be a feasible and successful option, even in complex cases involving multiple silver cone obturation.

Ethic approval

None

Acknowledgement

None

Funding source

None

Conflict of interest

None

References

1. Kehoe JC. Intracanal corrosion of a silver cone producing a localized argyria: scanning electron microscope and energy dispersive X-ray analyzer analyses. **J Endod**. 1984;10(5):199-201.
2. Seltzer S, Green DB, Weiner N, DeRenzis F. A scanning electron microscope examination of silver cones removed from endodontically treated teeth. **J Endod**. 2004;30(7):463-474.
3. Tomov G, Kovacevska G. Local Argyrosis of Oral Mucosa: Diagnostic and Treatment Considerations. **Int J Sci Res (IJSR)**. 2015;4(1):1254-1257.
4. American Association of Endodontists (AAE). Use of Silver Points: AAE Position Statement. Chicago: AAE; 2024. Available from: https://www.aae.org/specialty/wp-content/uploads/sites/2/2024/06/SilverPoints_PositionStatement.pdf2024.
5. Siqueira JF Jr, Rôças IN. Clinical implications and microbiology of bacterial persistence after treatment procedures. **J Endod**. 2008;34(11):1291-1301.e3.
6. Prada I, Micó-Muñoz P, Giner-Lluesma T, Micó-Martínez P, Collado-Castellano N, Manzano-Saiz A. Influence of microbiology on endodontic failure. Literature review. **Med Oral Patol Oral Cir Bucal**. 2019;24(3):e364-e372.
7. Tabassum S, Khan FR. Failure of endodontic treatment: The usual suspects. **Eur J Dent**. 2016;10(1):144-147.
8. Siqueira JF Jr. Aetiology of root canal treatment failure: why well-treated teeth can fail. **Int Endod J**. 2001;34(1):1-10.
9. Shetty K. Technique Tips – A Predictable Method for Retrieval of Silver Cones Using Ultrasonics. **Dent Update**. 2016;43(4):396-397.
10. Ruddle CJ. Nonsurgical retreatment. **J Endod**. 2004;30(12):827-845.
11. Sookprome C. Endodontic retreatment in tooth with silver cone : A case report. **J Prapokklao Hosp Clin Med Educat Center**. 2009:249-255.
12. Sanguandikul L. Removals of silver cones in non-surgical retreatment: A case report. **Vajira Med J**. 2015;59(3):67-74.
13. Weisman MI. The removal of difficult silver cones. **J Endod**. 1983;9(5):210-211.
14. Hülsmann M. Retrieval of silver cones using different techniques. **Int Endod J**. 1990;23(6):298-303.
15. Hülsmann M. Removal of silver cones and fractured instruments using the Canal Finder System. **J Endod**. 1990;16(12):596-600.
16. Krell KV, Fuller MW, Scott GL. The conservative retrieval of silver cones in difficult cases. **J Endod**. 1984;10(6):269-273.
17. Gulati S, Sumanthini M, Shenoy VU. Retreatment of Silver Point Obturation: A Case Report and an Overview. **J Contemp Dent**. 2012;2(3):114-118.